

# 2012 Updated Consensus Guidelines for the Management of Abnormal Cervical Cancer Screening Tests and Cancer Precursors

---

L. Stewart Massad, MD, Mark H. Einstein, MD, Warner K. Huh, MD,  
Hormuzd A. Katki, PhD, Walter K. Kinney, MD, Mark Schiffman, MD,  
Diane Solomon, MD, Nicolas Wentzensen, MD, and Herschel W. Lawson, MD,  
for the 2012 ASCCP Consensus Guidelines Conference

*From Washington University School of Medicine, St. Louis, Missouri; Albert Einstein College of  
Medicine, New York, New York; University of Alabama School of Medicine, Birmingham,  
Alabama; Division of Cancer Epidemiology and Genetics and Division of Cancer Prevention,  
National Cancer Institute, Bethesda, Maryland; The Permanente Medical Group, Sacramento,  
California; and Emory University School of Medicine, Atlanta, Georgia*

■ **ABSTRACT:** A group of 47 experts representing 23 professional societies, national and international health organizations, and federal agencies met in Bethesda, MD, September 14–15, 2012, to revise the 2006 American Society for Colposcopy and Cervical Pathology Consensus Guidelines. The group's goal was to provide revised evidence-based consensus guidelines for managing women with abnormal cervical cancer screening tests, cervical intraepithelial neoplasia (CIN) and adenocarcinoma in situ (AIS) following adoption of cervical cancer screening guidelines incorporating longer screening intervals and co-testing. In addition to literature review, data from almost 1.4 million women in the

These guidelines are being published simultaneously in *Obstetrics & Gynecology* and the *Journal of Lower Genital Tract Disease*. The complete algorithms are published in the *Journal of Lower Genital Tract Disease* and are also available on the web site of the American Society for Colposcopy and Cervical Pathology (<http://www.asccp.org/>).

The contents of this article are solely the responsibility of the authors and do not necessarily represent the official views of the National Institutes of Health or U.S. federal government.

Corresponding author: L. Stewart Massad, MD Division of Gynecologic Oncology, Washington University School of Medicine, 4911 Barnes-Jewish Hospital Plaza, St. Louis, MO 63110; e-mail: [massadl@wudosis.wustl.edu](mailto:massadl@wudosis.wustl.edu).

#### **Financial Disclosure**

*Dr. Massad has served as an expert witness. Dr. Huh has served as a consultant to Roche. Dr. Schiffman has researched reagents for Qiagen and Roche. The other authors did not report any potential conflicts of interest.*

Kaiser Permanente Northern California Medical Care Plan provided evidence on risk after abnormal tests. Where data were available, guidelines prescribed similar management for women with similar risks for CIN 3, AIS, and cancer. Most prior guidelines were reaffirmed. Examples of updates include: Human papillomavirus–negative atypical squamous cells of undetermined significance results are followed with co-testing at 3 years before return to routine screening and are not sufficient for exiting women from screening at age 65 years; women aged 21–24 years need less invasive management, especially for minor abnormalities; postcolposcopy management strategies incorporate co-testing; endocervical sampling reported as CIN 1 should be managed as CIN 1; unsatisfactory cytology should be repeated in most circumstances, even when HPV results from co-testing are known, while most cases of negative cytology with absent or insufficient endocervical cells or transformation zone component can be managed without intensive follow-up. ■

**B**y 2001, revised Bethesda system terminology for reporting cervical cytology results and the availability of findings from a recent randomized trial of strategies for managing minor cervical cytologic abnormalities had created the need for a standard approach to managing women with abnormal cervical cytology and cervical cancer precursors (1–3). In response, the American Society for Colposcopy and Cervical Pathology (ASCCP) initiated

a process that developed comprehensive, evidence-based consensus guidelines to aid clinicians in managing women with abnormal cervical cytology, cervical intra-epithelial neoplasia (CIN), and adenocarcinoma in situ (AIS) (4, 5). Although those guidelines became the standard for managing women with abnormal cervical cytology and cancer precursors, the need for revisions became apparent. A second consensus conference in 2006 aligned management of minor cytologic abnormalities and CIN 1, incorporated follow-up results of the ASCUS-LSIL Triage Study (ALTS), identified strategies for management of positive human papillomavirus (HPV) DNA tests, and established guidelines for management of adolescents and young women (6, 7).

As updated in 2001, the Bethesda System also defined terminology for cytologic specimen adequacy, and ASCCP developed management guidelines for women with unsatisfactory cytology results and for those with negative results but limited endocervical/transformation zone (EC/TZ) component (8). These guidelines were updated in 2008 (9) but were not validated by a national consensus conference.

Previous guidelines remain valid, but knowledge has advanced. Screening has changed. In 2012, national organizations published guidelines embracing longer screening intervals and a later age to start screening (10, 11). Co-testing with cytology and HPV testing at 5-year intervals is now the preferred or acceptable strategy for cervical cancer screening for women aged 30–64 years (10, 11). Clinicians should benefit from guidance on how to incorporate co-testing into management of women with cervical abnormalities.

In addition, new evidence to guide decisions about management of abnormal screening tests and CIN and AIS emerged in 2012 from analyses of the large clinical database at the Kaiser Permanente Northern California Medical Care Plan (KPNC), conducted in collaboration with scientists from the National Cancer Institute (NCI) (12). This new evidence fills gaps in the 2006 guidelines. For example, prior management guidelines relied heavily on data from ALTS, which provided evidence on initial management of women with minor cytologic abnormalities. Results were extrapolated to provide guidelines on management of women with more severe cytologic abnormalities and post-colposcopy follow-up. The newer evidence from KPNC analyses allows validation or modification of prior guidelines in specific areas. The size of the KPNC database also allows age-based stratification of data for some types of abnormalities. While these observational data from a single U.S. region may limit generalizability and the lack of follow-up

beyond 8 years may limit long-term risk estimates, publication of comparable analyses from similarly large databases soon is unlikely.

Finally, additional data have emerged in specific areas. Human papillomavirus genotyping tests have been approved; these have been recommended as an option for specific clinical scenarios to guide triage to colposcopy. More information is also available to guide management of women with unsatisfactory cytology.

In response, ASCCP conducted a consensus process to update the management of abnormal co-testing results and cytology with specimen adequacy limitations, the initial management of abnormal screening test results, options for postcolposcopy management, management of women aged 21–24 years, and other issues. This report details the consensus guidelines developed through this process.

## METHODS

The process for the 2012 consensus guidelines was similar to that for the previous guidelines (4–7). Initially the ASCCP Practice Committee defined questions for the 2012 consensus process. A steering committee of nationally recognized experts in cervical cancer prevention was nominated and canvassed for additional questions. At the March 2012 ASCCP Biennial Scientific Meeting, conference attendees presented suggestions for guidelines review. Organizations that participated in the 2006 guidelines development process were solicited to nominate representatives to the revision process and also were asked to identify questions for review. Participants and participating organizations are listed in Appendix A.

A multifaceted process was used to evaluate the evidence and resolve identified issues. Five working groups were created, chaired by steering committee members and including delegates from participating organizations. For some working groups, the MEDLINE database was queried using relevant key words for English-language articles published after 2005, the date of the last consensus conference review (see Appendix 1, available online at <http://links.lww.com/LGT/A9>). Potentially relevant abstracts from identified articles were reviewed. Reports were rated according to the strength and quality of relevant evidence.

Other working groups focused on analyses of outcomes risk from a database of 1.4 million women cared for at KPNC and followed from January 1, 2003 to December 31, 2010. The primary outcome of interest in these analyses was CIN 3+ (CIN 3, AIS, and cancer). Cancer was used as an outcome when risk was high and CIN 2+ (CIN 3+ and

CIN 2) was used when the number of CIN 3+ events was low. Applying the concepts of “similar management for similar risks,” risks were benchmarked to those for accepted management strategies. Since delegates considered zero cancer risk unattainable and CIN 3+ a reasonable proxy for cancer risk, acceptable risks were considered to be those approximating CIN 3+ risk 3 years after negative cytology or 5 years after negative co-testing. In brief, immediate colposcopy was recommended when the 5-year risk of CIN 3+ in the KPNC cohort exceeded 5%, a 6-month to 12-month return for risk of 2–5%, a 3-year return for risk of 0.1–2%, and a 5-year return interval for risk comparable to co-testing in women without a history of abnormality, or 0.1%. (12).

Draft guidelines developed by the working groups were posted to the ASCCP web site, and comments were solicited from collaborating organizations and the public. Draft guidelines revised in light of public comments were presented to a consensus conference convened September 14–15, 2012, at the Natcher Conference Center on the campus of the National Institutes of Health in Bethesda, MD. Draft guidelines and supporting evidence were presented, discussed, revised as needed, and adopted by at least 66% of voting delegates using electronic voting devices.

The terminology used in the updated guidelines is similar to prior versions, and the two-part rating system is the same (Table 1). Ratings are given in parentheses throughout the guidelines. The terms *recommended*, *preferred*, *acceptable*, and *unacceptable* are used in the guidelines to describe various interventions. A new term, “*not recommended*,” was added to describe management strategies with weak evidence against their use but only marginal risk for adverse consequences. The strength rating of a recommendation was based on the quality of evidence supporting it but incorporated other factors, including potential for harm if an intervention did not occur and potential complications from a given intervention.

For cytologic classification and assessment of cytology specimen adequacy, the 2001 Bethesda System was used (1). For histologic classification, a two-tiered system was employed. Low-grade lesions were termed CIN 1 and high-grade lesions were termed CIN 2 or CIN 3. Some pathologists do not distinguish CIN 2 from CIN 3, and these undifferentiated high-grade lesions are termed CIN 2,3.

## GUIDING PRINCIPLES

Participants at the consensus conference affirmed that the 2006 ASCCP guidelines for the management of abnormal cervical cancer screening tests (6) and CIN

**Table 1. Rating the Recommendations**

Strength of recommendation*	
A	Good evidence for efficacy and substantial clinical benefit support recommendation for use.
B	Moderate evidence for efficacy or only limited clinical benefit supports recommendation for use.
C	Evidence for efficacy is insufficient to support a recommendation for or against use, but recommendations may be made on other grounds.
D	Moderate evidence for lack of efficacy or for adverse outcome supports a recommendation against use.
E	Good evidence for lack of efficacy or for adverse outcome supports a recommendation against use.
Quality of evidence*	
I	Evidence from at least one randomized, controlled trial.
II	Evidence from at least one clinical trial without randomization, from cohort or case-controlled analytic studies (preferably from more than one center), or from multiple time-series studies, or dramatic results from uncontrolled experiments.
III	Evidence from opinions of respected authorities based on clinical experience, descriptive studies, or reports of expert committees.
Terminology used for recommendations†	
Recommended	Good data to support use when only one option is available.
Preferred	Option is the best (or one of the best) when there are multiple options.
Acceptable	One of multiple options when there is either data indicating that another approach is superior or when there are no data to favor any single option.
Not recommended	Weak evidence against use and marginal risk for adverse consequences.
Unacceptable	Good evidence against use.

\* Modified from Gross PA, Barrett TL, Dellinger EP, et al. Purpose of quality standards for infectious diseases. Infectious Diseases Society of America. Clin Infect Dis 1994;18:421-98. Kish MA. Guide to development of practice guidelines. Clin Infect Dis 2001;32:851-4.  
† The assignment of these terms represents an opinion ratified by vote during the 2012 consensus conference.

or AIS (7) remain valid, with the exception of the specific areas reviewed. Those earlier guidelines have been combined with current revisions in this document to provide comprehensive recommendations for management. Changes are summarized in Box 1.

Cervical cancer prevention is a process with benefits and harms. Risk cannot be reduced to zero with currently available strategies, and attempts to achieve zero risk may result in unbalanced harms, including overtreatment. As noted in a 2011 consensus conference on cervical cancer screening (10), optimal prevention strategies should identify those HPV-related abnormalities likely to progress to invasive cancers while avoiding destructive treatment of abnormalities not destined to become cancerous. Adopted management strategies provide what participants considered an acceptable level of risk of failing to detect high-grade neoplasia or cancer in a given clinical situation. Where data were available,

### Box 1. Essential Changes From Prior Management Guidelines\*

- Cytology reported as negative but lacking endocervical cells can be managed without early repeat.
- CIN 1 on endocervical curettage should be managed as CIN 1, not as a positive ECC.
- Cytology reported as unsatisfactory requires repeat even if HPV negative.
- Genotyping triages HPV-positive women with HPV type 16 or type 18 to earlier colposcopy only after negative cytology; colposcopy is indicated for all women with HPV and ASC-US, regardless of genotyping result.
- For ASC-US cytology, immediate colposcopy is not an option. The serial cytology option for ASC-US incorporates cytology at 12 months, not 6 months and 12 months, and then if negative, cytology every 3 years.
- HPV-negative and ASC-US results should be followed with co-testing at 3 years rather than 5 years.
- HPV-negative and ASC-US results are insufficient to allow exit from screening at age 65 years.
- The pathway to long-term follow-up of treated and untreated CIN 2+ is more clearly defined by incorporating co-testing.
- More strategies incorporate co-testing to reduce follow-up visits. Pap-only strategies are now limited to women younger than 30 years, but co-testing is expanded even to women younger than 30 years in some circumstances. Women aged 21-24 years are managed conservatively.

*CIN, cervical intraepithelial neoplasia; ECC, endocervical curettage; HPV, human papillomavirus; ASC-US, atypical squamous cells of undetermined significance. \*Prior management guidelines were from the "2006 Consensus Guidelines for the Management of Women With Abnormal Cervical Screening Tests" (6). Prior guidelines not changed were retained.*

similar management strategies were prescribed for similar levels of risk (12, 13). Guidelines cannot be developed for all situations. Clinical judgment should always be applied when applying guidelines to individual patients. This is especially true for guidelines based on less robust evidence.

In 2012, the Lower Anogenital Squamous Terminology (LAST) Project created new terminology for HPV-related lesions of the lower genital tract (14). However, delegates to the current consensus process determined that this classification does not yet have a sufficiently robust outcomes evidence base to allow elucidation of risk-based management guidelines (see Box 2).

Algorithms detailing the different management recommendations are available at the ASCCP web site ([www.asccp.org/consensus2012](http://www.asccp.org/consensus2012)). A glossary of terms used in the guidelines is in Appendix B.

In the 2006 ASCCP guidelines,(6,7) several pathways concluded by returning women to "routine screening." This term was not defined, but in 2006, screening guidelines prescribed cytology at shorter intervals than now recommended. Current 2011 screening guidelines recommend either 3-year cytology intervals or, for women aged 30–64 years, 5-year co-testing intervals (10, 11). These multi-year intervals are safe only when risk for the development of CIN 3+ during the years between testing is low (10, 11). For example, women aged 30–64 years with a negative co-test have a 5-year

risk of CIN 3+ of only 8/10,000 (12). Although this low level of risk can be achieved among women with negative screening histories, for those with some abnormalities, risk for CIN 3+ remains elevated for years, even after treatment and even after initial negative surveillance. After some abnormalities, current follow-up data are insufficient to define a pathway to return to 5-year routine screening intervals because even with treatment, risk does not fall to a level consistent with 5-year retesting.

When, how, and even whether to perform endocervical sampling is controversial. Endocervical brushing has better sensitivity than curettage with similar specificity, better tolerance, and fewer insufficient samples, although grading may be more difficult because stroma is rarely sampled with brushing (15, 16). Either is acceptable for endocervical sampling. In 2006, working groups assessing management of cytology reported as atypical squamous cells of undetermined significance (ASC-US) and low-grade squamous intraepithelial lesions (LSIL) defined indications for endocervical sampling, guidance that should be valid for women with cytology results of atypical squamous cells, cannot exclude high-grade squamous intraepithelial lesions (ASC-H) and high-grade squamous intraepithelial lesions (HSIL) as well.

Management strategies incorporate HPV testing based on studies using validated HPV assays. Management based on results of HPV tests not similarly validated may not result in intended outcomes and may risk patient harm. These guidelines are intended for use only with HPV tests that have been analytically and clinically validated with proven acceptable reproducibility, clinical sensitivity, specificity, and positive and negative predictive values for cervical cancer and verified precancer (CIN 2+), as documented by U.S. Food and Drug Administration (FDA) licensing and approval or publication in peer-reviewed scientific literature. Testing should be restricted to high-risk (oncogenic) HPV types (mainly 16, 18, 31, 33, 35, 39, 45, 51, 52, 56, 58, and 59), and in these guidelines "HPV testing" refers only to testing for high-risk

### Box 2.

A recent consensus conference (the Lower Anogenital Squamous Terminology [LAST] Project convened by the College of American Pathologists and the American Society for Colposcopy and Cervical Pathology) adopted a two-tier terminology that incorporates ancillary tests and other criteria to distinguish indeterminate lesions as high grade or low grade. Until a comprehensive evidence review and consensus guidelines development process can be conducted, histopathology results reported as low-grade squamous intraepithelial lesions (LSIL) should be managed as cervical intraepithelial neoplasia (CIN) 1 and those reported as high-grade squamous intraepithelial lesions (HSIL) should be managed as CIN 2,3 (14).

(oncogenic) HPV types. Testing for low-risk (nononcogenic) HPV types has no role in the evaluation of women with abnormal cervical cytologic results.

Both ablation and excision effectively treat CIN. Randomized trials comparing different modalities show similar efficacy (17–20). Efficacy rates range from 90% to 95%, and most failures occur within 2 years (21), although cancers can develop up to 20 years after treatment (22). Margin status is a convenient predictor of recurrence and a traditional risk marker, although it does not appear to be an independent risk factor (23, 24). Nonsurgical therapies, including topical agents and therapeutic vaccines, remain investigational.

A wide variety of follow-up approaches have been described for women treated for CIN, incorporating cytology, HPV testing, and colposcopy alone or in combination at intervals from 3 months to annually. HPV testing is more sensitive but less specific than cytology in posttreatment follow-up and it may result in earlier diagnosis of persistent or recurrent disease (25). Protocols for follow-up after treatment of CIN have not been evaluated as primary interventions in randomized trials.

Under the 2011 screening guidelines, women followed after positive HPV tests but negative cytology were referred to colposcopy only if they had LSIL or more severe cytology or a positive HPV test during surveillance co-testing (10). However, only 0.04% of all women aged 30–64 years in the KPNC database had HPV-negative ASC-US after an HPV-positive, cytology negative result (26), so referring these women for colposcopy will burden care systems minimally. Thus, for simplicity, current guidelines recommend colposcopy for any positive HPV test or any abnormal cytology during follow-up.

Studies of the effect of treatment on future pregnancy are conflicting, although many indicate an approximately two-fold increase in preterm delivery risk (27–29). Although not proven, this is presumed to result from deficient cervical stroma, and risk appears to increase with the volume and number of excisions (30). However, many studies were done in countries where loop excisions are performed with larger loop sizes and deeper excisions than most U.S. clinicians employ. Studies linking ablative treatments to preterm delivery are even more limited and conflicting. Women with CIN may be at increased risk for preterm delivery even when untreated. Nevertheless, because pregnancy complications can be devastating, the potential benefits of treatment should be balanced against the risk to

future pregnancies. Young women have high regression rates for cervical disease and low cancer risk (31–33). The term “young women” indicates those who after counseling by their clinicians consider risk to future pregnancies from treating cervical abnormalities to outweigh risk for cancer during observation of those abnormalities. No specific age threshold is intended.

In 2006, guidelines recommended less aggressive management for adolescents with cervical abnormalities (6, 34), but these are now moot because the 2011 screening guidelines recommend not screening adolescents (10, 11). Delegates to the 2012 consensus conference considered less intensive management for other young women with abnormal cytology. Cervical cancer risk remains low through age 25 years (35), HPV is common (36), and lesions often regress (37). The annual incidence of cervical cancer among U.S. women aged 21–24 years is 1.4/100,000, and almost 55,000 cytology tests must be obtained for every cervical cancer diagnosed in this age group (35). This level of risk is 10-fold higher than risk in adolescents and appears to be high enough to justify screening yet is low enough to allow observation for minor cytologic abnormalities. Guidelines for women aged 21–24 years can be extrapolated to adolescents inadvertently screened.

Interventions for abnormal screening tests and CIN or AIS have other consequences that are not easily measurable. Women experience emotional distress when receiving abnormal cytology and HPV test results, when having colposcopy even when findings are normal, and when undergoing cervical treatment. Emotional distress is usually prompted by uncertainty and anticipation of the unknown (38). Many management strategies incorporate follow-up with HPV testing, which can elicit feelings of stigma and shame when positive despite the near-ubiquitous frequency of HPV infection (39, 40). The anxiety and time required for visits to manage abnormal cytology can adversely affect relationships, work-related and school activities, and family matters (41). These potential harms reinforce the concept that colposcopy and other interventions should be avoided when risk for CIN 3+ is low and when identified lesions are likely to resolve.

In the 2001 guidelines (4), separate recommendations for ASC-US management were developed for women infected with human immunodeficiency virus and other immunosuppressive conditions. Data review in 2006 eliminated these separate guidelines. Immunosuppressed women with abnormal results should be managed in the same manner as immunocompetent women.

Guidelines on management apply only to women undergoing routine screening with adequate visualization of the cervix and directed sampling with acceptable collection instruments. They also apply only to women identified with abnormalities during screening. Women with postcoital or unexplained abnormal vaginal bleeding, pelvic pain, abnormal discharge, or a visible lesion merit individualized evaluations.

Consensus guidelines from the ASCCP have international influence. However, they are tailored to the opportunistic cervical cancer screening system of the United States, with specific terminology, diagnostic criteria, pathways to colposcopic training, patient expectations and adherence, and medical–legal risks. Clinicians elsewhere must consider the guidelines in light of their own context and adapt management accordingly.

## MANAGEMENT OF ABNORMAL SCREENING TESTS

### Unsatisfactory Cytology

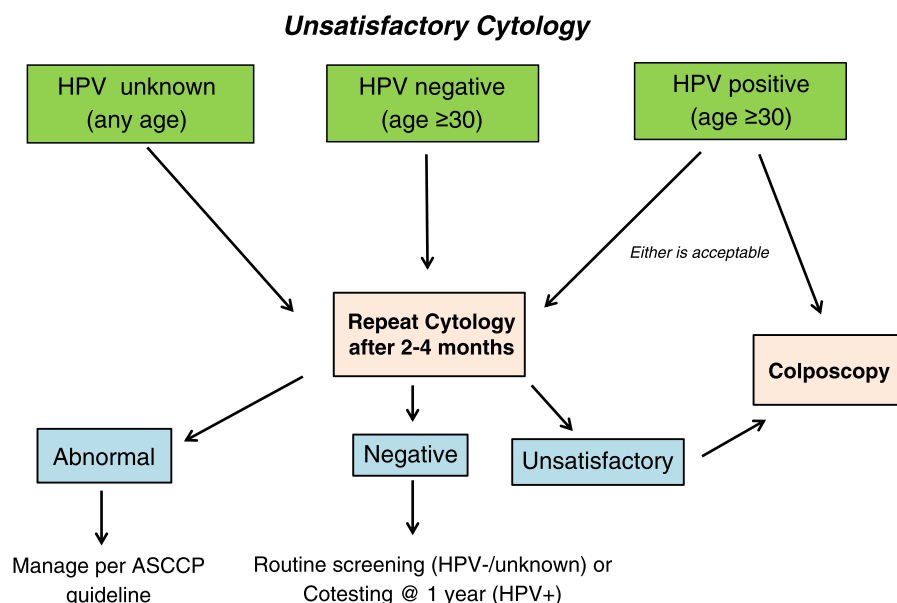
Cytology results are unsatisfactory for 1% or less across all preparation types (42, 43). Unsatisfactory cytology specimens are unreliable for detecting epithelial abnormalities. However, most studies that found a higher risk of disease among women with unsatisfactory cytology employed conventional Pap tests that can be rendered unsatisfactory by obscuring blood, inflammation, or

other processes (44, 45). Now that most U.S. cytology is done using liquid-based media, which can control for most obscuring factors in processing, unsatisfactory results arise largely from insufficient squamous cells (46). Evidence is sparse governing management of women with unsatisfactory cytology obtained as part of co-testing, although risk for high-grade disease in women with negative HPV tests appears to be low (47). Unsatisfactory results arise largely from insufficient squamous cells (48). Some currently available HPV tests lack a control for epithelial cellularity, so a negative HPV test cannot be relied upon as the HPV test may be falsely negative because of an insufficient sample.

Specimen collection techniques to minimize unsatisfactory cytology have not changed since the last guideline (9). Extended-tip spatulas, spatulas plus brushes, and brooms all appear effective (49, 50). When two devices are used, the ectocervical device should be used first.

### Management of Women With Unsatisfactory Cytology (Fig. 1)

For women with an unsatisfactory cytology result and no, unknown, or a negative HPV test result, repeat cytology in 2–4 months is recommended (BIII). Triage using reflex HPV testing is not recommended (BIII). Treatment to resolve atrophy or obscuring inflammation when a specific infection is present is acceptable (CIII).



© Copyright , 2013, American Society for Colposcopy and Cervical Pathology. All rights reserved. ASCCP

Figure 1.

For women aged 30 years and older who are co-tested and have unsatisfactory cytology and a positive HPV test, repeat cytology in 2–4 months or colposcopy is acceptable (BII). Colposcopy is recommended for women with two consecutive unsatisfactory cytology tests (CIII).

### Cytology Reported as Negative but With Absent or Insufficient EC/TZ Component

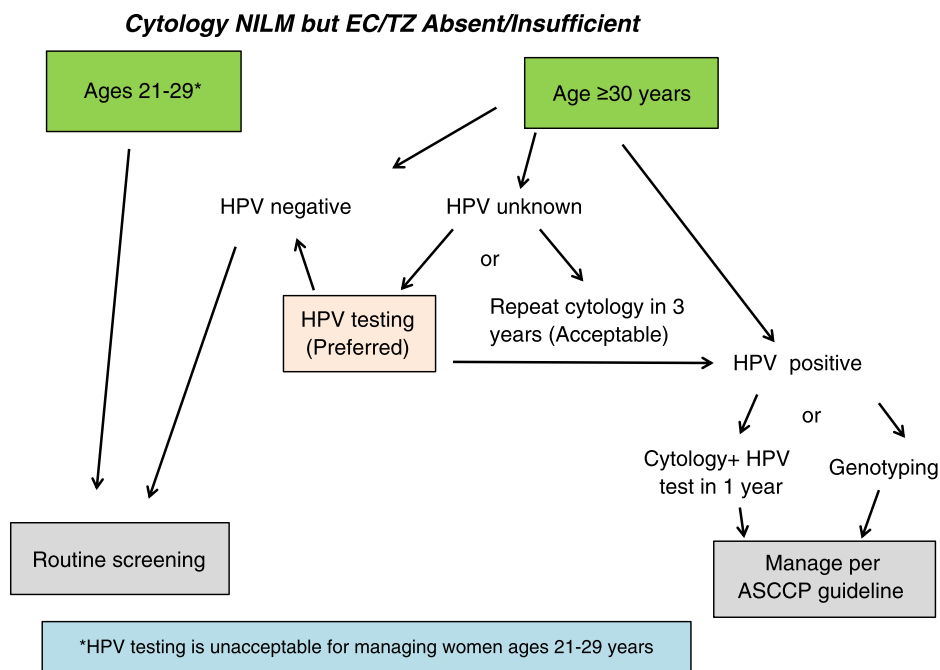
Cytology reported as negative but with absent or insufficient EC/TZ component has adequate cellularity for interpretation but lacks endocervical or metaplastic cells, suggesting that the squamocolumnar junction may not have been adequately sampled. This raises concern for missed disease. Recently reported rates of cytology results reported as negative but with absent or insufficient EC/TZ component have ranged from 10% to 20% and are higher in older women (51, 52). Prior guidelines recommended early repeat cytology (8, 9). However, while women with absent or insufficient EC/TZ component have fewer concurrent cytologic abnormalities, they do not have a higher risk for CIN 3+ over time than women with a satisfactory EC/TZ component, as would be expected if true precancers had been missed. Instead, the lower rate of cytologic abnormality appears to occur because women whose cytology lacks a satisfactory EC/TZ component are older, and older women have lower

CIN 3+ risk (53). A recent meta-analysis found that negative cytology had good specificity and negative predictive value despite absent or insufficient EC/TZ component (54). HPV testing appears to be independent of transformation zone sampling (55) and offers an added margin of safety for women aged 30–64 years now that co-testing is the preferred screening strategy for that age group. An absent EC/TZ component is not associated with an increased incidence of cervical disease after treatment of CIN 2+ (56).

### Management of Women With Cytology Reported as Negative but With Absent or Insufficient EC/TZ Component (Fig. 2)

For women aged 21–29 years with negative cytology and absent or insufficient EC/TZ component, routine screening is recommended. HPV testing is unacceptable (BIII).

For women aged 30 years and older with cytology reported as negative and with absent or insufficient EC/TZ component and no or unknown HPV test result, HPV testing is preferred (BIII). Repeat cytology in 3 years is acceptable if HPV testing is not performed (BIII). If the HPV test is done and is negative, return to routine screening is recommended (BIII). If the HPV test is positive, repeating both tests in 1 year is acceptable (BIII). Genotyping is also acceptable; if HPV type 16 or type 18 is present, colposcopy is



© Copyright, 2013, American Society for Colposcopy and Cervical Pathology. All rights reserved. ASCCP

Figure 2.

recommended (BII). If HPV type 16 and type 18 are absent, repeat co-testing in 12 >months is recommended (BIII).

**Negative Cytology With a Positive HPV Test**

Although not indicated for younger women, co-testing is the preferred screening strategy for women aged 30–64 years (10). Despite negative cytology, women with oncogenic HPV are at higher risk for later CIN 3+ than women with negative HPV tests (57). The risk of CIN 3+ in HPV positive but cytology negative women is sufficient to justify early return for retesting. Persistent HPV positivity increases risk still further (58, 59). However, most HPV infections are cleared, substantially reducing risk of CIN 3+ (60), so observing women to allow clearance is attractive. Nevertheless, CIN 3+ does occur during observation, requiring guidelines to balance risks arising from intervention for HPV that may yet be cleared against the risks of disease. This is true even for women with HPV infections but negative cytology. In the KPNC cohort, the CIN 3+ risk for every co-test result obtained after an initial HPV-positive but cytology-negative result was higher than risk associated with that co-test result in women with prior negative screening (58).

Women with HPV-16 are at particular risk for CIN 3+. Human papillomavirus-18 merits special consideration because of its association with cervical adenocarcinomas, which are less efficiently detected by cytology than squamous cancers.

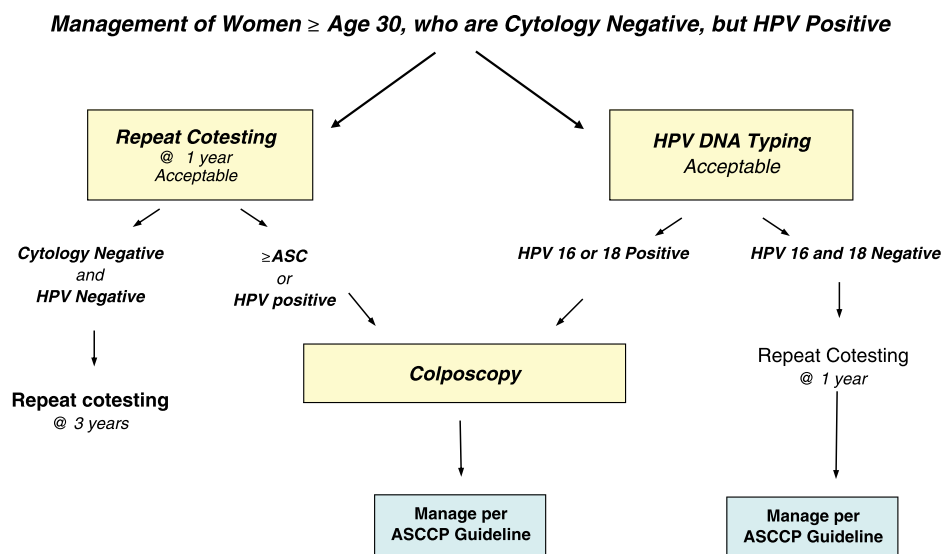
**Management of Women Testing HPV Positive but Cytology Negative (Fig. 3)**

For women 30 years of age and older with HPV-positive but cytology-negative co-testing, repeat co-testing at 1 year is acceptable (BII). At the 1-year repeat co-test, if the HPV test is positive or cytology is ASC-US or worse, colposcopy is recommended (BII). If the 1-year repeat co-test result is HPV negative and cytology negative, repeat co-testing in 3 years is recommended (BII).

HPV genotyping is also acceptable. If HPV-16 or HPV-18 tests are positive, colposcopy is recommended (BII). If HPV-16 and HPV-18 tests are negative, repeat co-testing in 1 year is recommended (BII).

**Atypical Squamous Cells of Undetermined Significance (ASC-US)**

ASC-US is the most common cytologic abnormality, but it carries the lowest risk of CIN 3+, partly because one third to two thirds are not HPV-associated (2, 26). In ALTS, three management strategies performed similarly and were included in subsequent guidelines (3, 4, 6). Compared with colposcopy for all ASC-US, reflex testing followed by colposcopy for HPV-positive women was preferred because it identified most CIN 3 lesions yet referred many fewer women to colposcopy (3). ALTS was conducted before the 2001 Bethesda system update, which separated ASC-H cytology from the ASC-US category. For this and other reasons, the observed 3%



© Copyright , 2013, American Society for Colposcopy and Cervical Pathology. All rights reserved. ASCCP

Figure 3.



5-year risk of CIN 3+ after ASC-US among women aged 30 years and older in the KPNC cohort was lower than the 2-year risk seen in ALTS. In fact, risk was low enough to justify annual rather than semiannual cytology as sufficiently sensitive to identify women with CIN 3+ (61).

Recent 2011 screening guidelines recommended that women with HPV-negative ASC-US co-testing results be managed with routine follow-up (10). This was based on an earlier analysis of a smaller KPNC dataset. Analysis of an expanded dataset found that while the absolute risk of CIN 3+ was low after HPV-negative ASC-US, it was more comparable to CIN 3+ risk among women with negative cytology alone than those with a negative co-test (26), suggesting a 3-year interval for follow-up. In addition, women over 60 years of age with HPV-negative ASC-US had a higher risk for cervical cancer during follow-up than women with negative co-testing, suggesting that they need continued screening.

Triage using HPV genotyping was considered. Women with ASC-US who also had HPV-16 or HPV-18 detected had approximately twice the risk of CIN 3+ as women with ASC-US and high-risk HPV types other than 16 or 18 (61–63). Nevertheless, KPNC data showed that the risk for CIN 3+ in both groups exceeded the threshold for colposcopy (26). HPV-16/18 genotyping of HPV-positive women with ASC-US did not appear to lead to different management.

No new information that would change the 2006 guidelines was identified on ASC-US in pregnant or postmenopausal women.

#### Management of Women with ASC-US (Fig. 4)

For women with ASC-US cytology, reflex HPV testing is preferred (BI). For women with HPV-negative ASC-US, whether from reflex HPV testing or co-testing, repeat co-testing at 3 years is recommended (BII). For women with HPV-positive ASC-US, whether from reflex HPV testing or co-testing, colposcopy is recommended (BI). When colposcopy does not identify CIN in women with HPV-positive ASC-US, co-testing at 12 months is recommended (BII). If the co-test is HPV negative and cytology negative, return for age-appropriate testing in 3 years is recommended (BII). If all tests are negative at that time, routine screening is recommended (BIII). It is recommended that HPV testing in follow-up after colposcopy not be performed at intervals of less than 12 months (EIII).

For women with ASC-US cytology and no HPV result, repeat cytology at 1 year is acceptable (BII). If the result is ASC-US or worse, colposcopy is recommended; if the result is negative, return to cytology testing at 3-year intervals is recommended (BII).

Endocervical sampling is preferred for women in whom no lesions are identified (BII) and for those with an

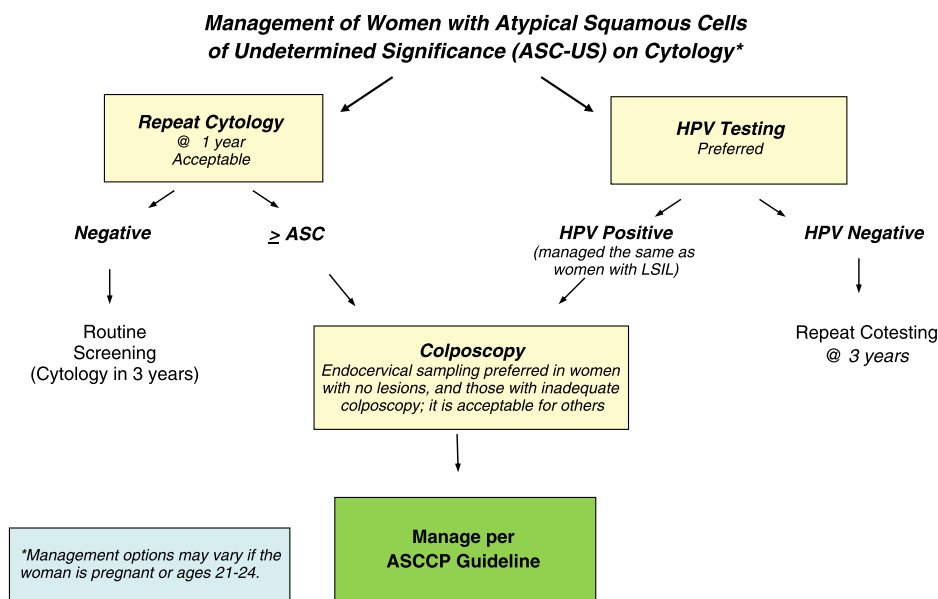
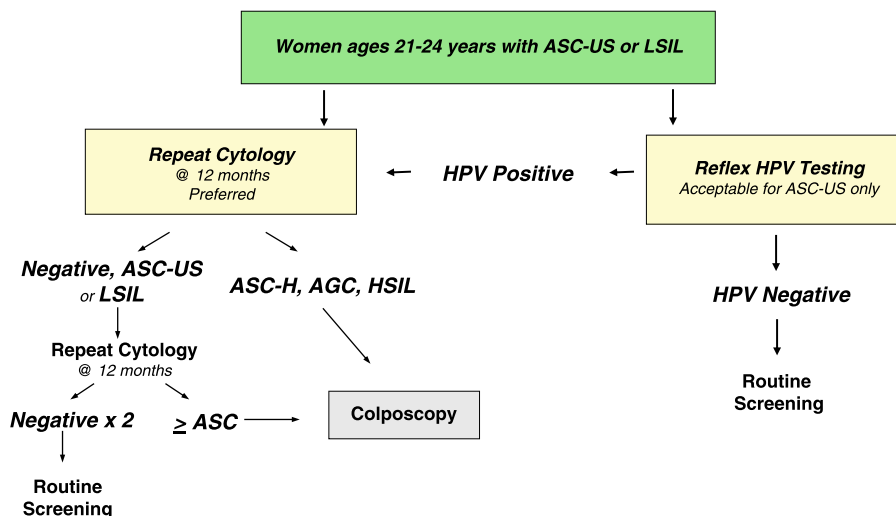


Figure 4.

**Management of Women Ages 21-24 years with either Atypical Squamous Cells of Undetermined Significance (ASC-US) or Low-grade Squamous Intraepithelial Lesion (LSIL)**



© Copyright, 2013, American Society for Colposcopy and Cervical Pathology. All rights reserved. ASCP

Figure 5.

inadequate colposcopy (AII) but is acceptable for women with an adequate colposcopy and a lesion identified in the transformation zone (CII).

Because of the potential for overtreatment, the routine use of diagnostic excisional procedures such as loop electrosurgical excision for women with an initial ASC-US in the absence of CIN 2+ is unacceptable (EII).

### ASC-US in Special Populations

#### Women Aged 21–24 years (Fig. 5)

##### Initial Management

For women aged 21–24 years with ASC-US, cytology alone at 12-month intervals is preferred, but reflex HPV testing is acceptable (BII). If reflex HPV testing is performed with ASC-US and the HPV result is positive, repeat cytology in 12 months is recommended (BII). Immediate colposcopy or repeat HPV testing is not recommended. If reflex HPV testing is performed and is negative, return for routine screening with cytology alone in 3 years is recommended (BII).

##### Follow-Up

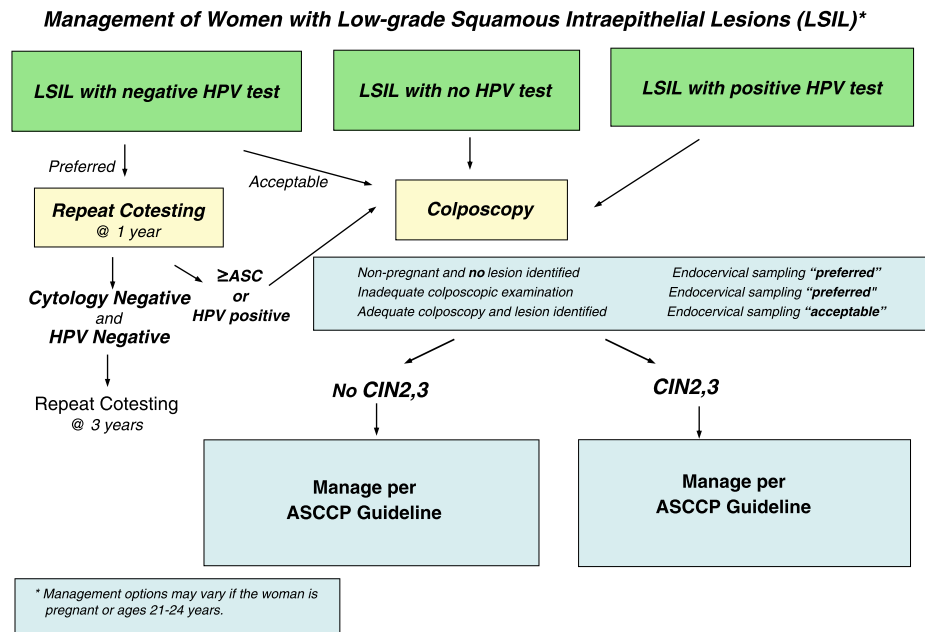
For women with ASC-US who are aged 21–24 years, follow-up with cytology at 12-month intervals is recommended. Colposcopy is not recommended. (BII) For women with ASC-H or HSIL+ (HSIL, atypical glandular cells [AGC], or cancer) at the 12-month follow up, colposcopy is recommended. For women with ASC-US or

worse at the 24-month follow-up, colposcopy is recommended. For women with two consecutive negative results, return to routine screening is recommended. (BII)

**Women Aged 65 Years and Older.** Postmenopausal women with ASC-US should be managed in the same manner as women in the general population, except when considering exit from screening for women aged 65 years and older. For those women, HPV-negative ASC-US results should be considered abnormal (AII). Additional surveillance is recommended with repeat screening in 1 year; co-testing is preferred but cytology is acceptable (BII).

**Pregnant Women.** Management options for pregnant women with ASC-US are identical to those described for nonpregnant women, with the exception that deferring colposcopy until 6 weeks postpartum is acceptable (CIII). Endocervical curettage in pregnant women is unacceptable (EIII). For pregnant women who have no cytologic, histologic, or colposcopically suspected CIN 2+ at the initial colposcopy, postpartum follow-up is recommended (BIII).

**Postmenopausal Women.** Postmenopausal women with ASC-US should be managed in the same manner as women in the general population (BII).



© Copyright , 2013, American Society for Colposcopy and Cervical Pathology. All rights reserved. ASCCP

**Figure 6.**

### Low-Grade Squamous Intraepithelial Lesion

The ASCUS-LSIL Triage Study showed that the natural history of LSIL approximates that of HPV-positive ASC-US (64), suggesting that women with either should be managed similarly. Analysis of the KPNC dataset confirmed that women with LSIL at ages 21–24 years carry a lower risk of CIN 3+ than older women (33, 65). Low-grade squamous intraepithelial lesions are highly associated with HPV infection, with a pooled estimate of HPV positivity of 77% (66). This rate appears too high to allow reflex HPV testing to select women for colposcopy efficiently. However, when co-testing is performed in women 30 years of age and older, some women have HPV-negative LSIL. In the KPNC cohort, the risk of CIN 3+ in HPV-negative women with LSIL was low, similar to that of ASC-US alone (67).

#### Management of Women with LSIL (Fig. 6)

For women with LSIL cytology and no HPV test or a positive HPV test, colposcopy is recommended (AI). If co-testing shows HPV-negative LSIL, repeat co-testing at 1 year is preferred, but colposcopy is acceptable. If repeat co-testing at 1 year is elected, and if the cytology is ASC-US or worse or the HPV test is positive (ie, if the co-testing result is other than HPV negative, cytology negative), colposcopy is recommended. If the co-testing result at 1 year is HPV negative and cytology negative, repeat

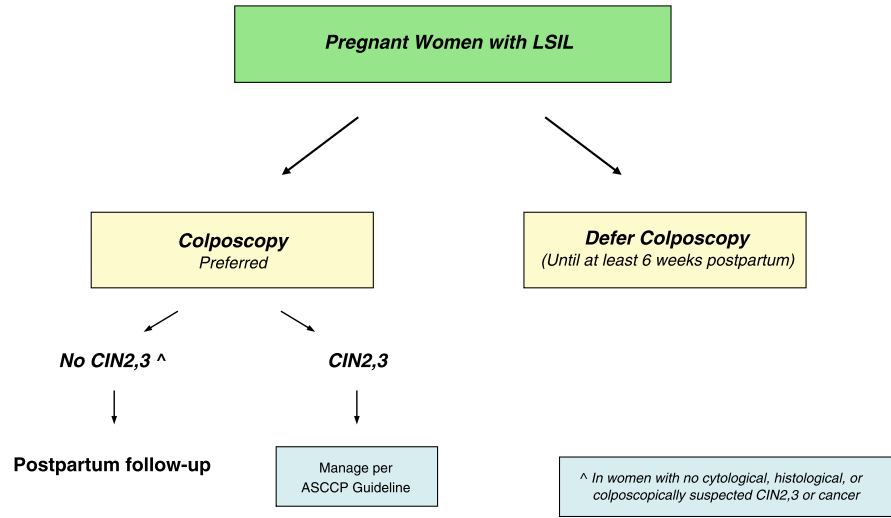
co-testing after an additional 3 years is recommended. If all tests are negative at that time, routine screening is recommended (BIII).

#### LSIL in Special Populations

**Women Aged 21–24 Years (Fig. 5).** For women with LSIL who are aged 21–24 years, follow-up with cytology at 12-month intervals is recommended (BII). Colposcopy is not recommended (DII). For women with ASC-H or HSIL+ at the 12-month follow up, colposcopy is recommended. For women with ASC-US or worse at the 24-month follow up, colposcopy is recommended. For women with two consecutive negative results, return to routine screening is recommended (BII).

**Pregnant Women (Fig. 7).** For pregnant women with LSIL, colposcopy is preferred (BII). Endocervical curettage in pregnant women is unacceptable (EIII). For pregnant women aged 21–24 years, follow-up according to the guidelines for management of LSIL in women aged 21–24 years is recommended (discussed in previous paragraph). Deferring colposcopy until 6 weeks postpartum is acceptable (CIII). For pregnant women who have no cytologic, histologic, or colposcopically suspected CIN 2+ at the initial colposcopy, postpartum follow-up is recommended (BIII). Additional colposcopic and cytologic

**Management of Pregnant Women with Low-grade Squamous Intraepithelial Lesion (LSIL)**



© Copyright , 2013, American Society for Colposcopy and Cervical Pathology. All rights reserved. ASCCP

Figure 7.

examinations during pregnancy are unacceptable for these women (DIII).

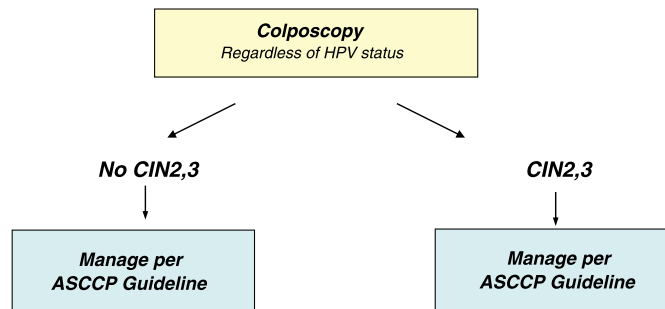
**Postmenopausal Women.** Acceptable options for the management of postmenopausal women with LSIL and no HPV test include obtaining HPV testing, repeat cytologic testing at 6 months and 12 months, and colposcopy (CIII). If the HPV test is negative or if CIN is not identified at colposcopy, repeat cytology in 12 months is

recommended. If either the HPV test is positive or repeat cytology is ASC-US or greater, colposcopy is recommended (AII). If two consecutive repeat cytology tests are negative, return to routine screening is recommended. (BII)

**Atypical Squamous Cells, Cannot Exclude High-Grade Squamous Intraepithelial Lesion (ASC-H)**

Data from KPNC confirmed that a report of ASC-H confers higher risk for CIN 3+ over time than ASC-US or

**Management of Women with Atypical Squamous Cells: Cannot Exclude High-grade SIL (ASC-H)\***



\* Management options may vary if the woman is pregnant or ages 21-24 years.

© Copyright , 2013, American Society for Colposcopy and Cervical Pathology. All rights reserved. ASCCP

Figure 8.

**Management of Women Ages 21-24 yrs with Atypical Squamous Cells, Cannot Rule Out High Grade SIL (ASC-H) and High-grade Squamous Intraepithelial Lesion (HSIL)**

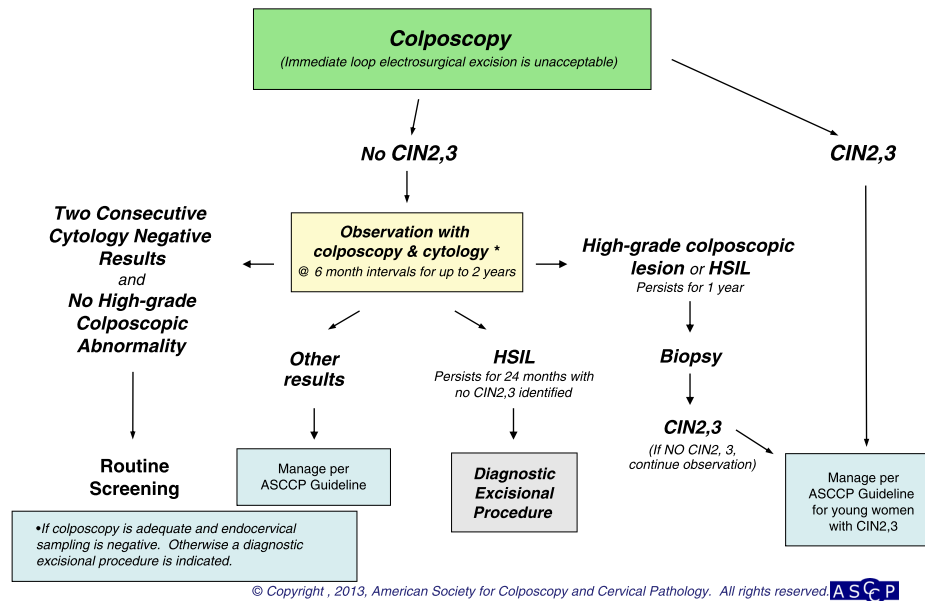


Figure 9.

LSIL (68, 69), although risk is lower than that following HSIL. This is also true for women aged 21–24 years, although their risk of CIN 3+ is lower than that for older women with ASC-H (33). The high rate of HPV detection in women with ASC-H makes reflex HPV testing unsuitable (3). In addition, the 5-year cancer risk among women with HPV-negative ASC-H is 2%, which is too high to justify observation (68).

**Management of Women With ASC-H (Fig. 8).** For women with ASC-H cytology, colposcopy is recommended regardless of HPV result. Reflex HPV testing is not recommended (DII).

### ASC-H in Special Populations

#### Women Aged 21–24 Years (Fig. 9)

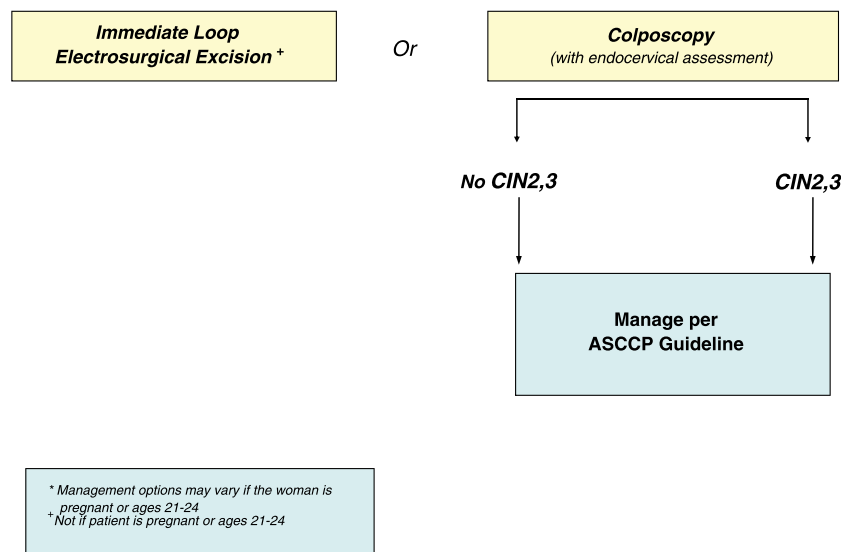
Colposcopy is recommended (AII). Further management should follow guidelines for women aged 21–24 years with HSIL.

#### High-Grade Squamous Intraepithelial Lesion (HSIL)

HSIL cytology results identify women at substantial risk. CIN 2+ is found at colposcopy in some 60% of women with HSIL (69–71). This justifies immediate excision of the transformation zone for many women, especially those who are at risk for loss to follow-up or who have completed childbearing. Cervical cancer is found at

colposcopy in some 2% of women with HSIL, although risk rises with age and is low among women aged 21–24 years, even with follow-up (33). Five-year cervical cancer risk is 8% among women 30 years of age and older (72). Risks are modified by HPV test results: HPV-negative HSIL co-test results, although uncommon, still carry a 5-year risk for CIN 3+ of 29%, while 7% will develop cancer (72). This precludes reflex HPV triage for HSIL. In the KPNC cohort, among women 30 years of age and older with HPV-positive HSIL, the 5-year risk of CIN 3+ was 50%, while the 5-year cancer risk was 7% (72). When HPV results are known from co-testing for women with HSIL, these risks may inform the choice between immediate diagnostic excision and colposcopy and between diagnostic excision and cytologic and colposcopic surveillance when CIN 2+ is not identified. The sensitivity of colposcopy for detecting CIN 2+ is lower than previously appreciated (73–75), and multiple biopsies should be considered at colposcopy when large confluent or multiple discrete lesions are seen.

**Management of Women With HSIL (Fig. 10).** For women with HSIL cytology, immediate loop electro-surgical excision or colposcopy is acceptable, except in special populations (BII). Triage using either a program of repeat cytology alone or reflex HPV testing is unacceptable (EII). For women not managed with immediate excision, colposcopy is recommended regardless of HPV

**Management of Women with High-grade Squamous Intraepithelial Lesions (HSIL)\***

© Copyright , 2013, American Society for Colposcopy and Cervical Pathology. All rights reserved. ASCCP

**Figure 10.**

result obtained at co-testing (BII). Accordingly, reflex HPV testing is not recommended (BII).

A diagnostic excisional procedure is recommended for women with HSIL when the colposcopic examination is inadequate, except during pregnancy (BII). Women with CIN 2, CIN 3, and CIN 2,3 should be managed according to the appropriate 2012 consensus guideline (see “Management of Women With CIN 2, CIN 3, and CIN 2,3”). Ablation is unacceptable in the following circumstances: when colposcopy has not been performed, when CIN 2,3 is not identified histologically, and when the endocervical assessment identifies CIN 2, CIN 3, CIN 2,3 or ungraded CIN (EII).

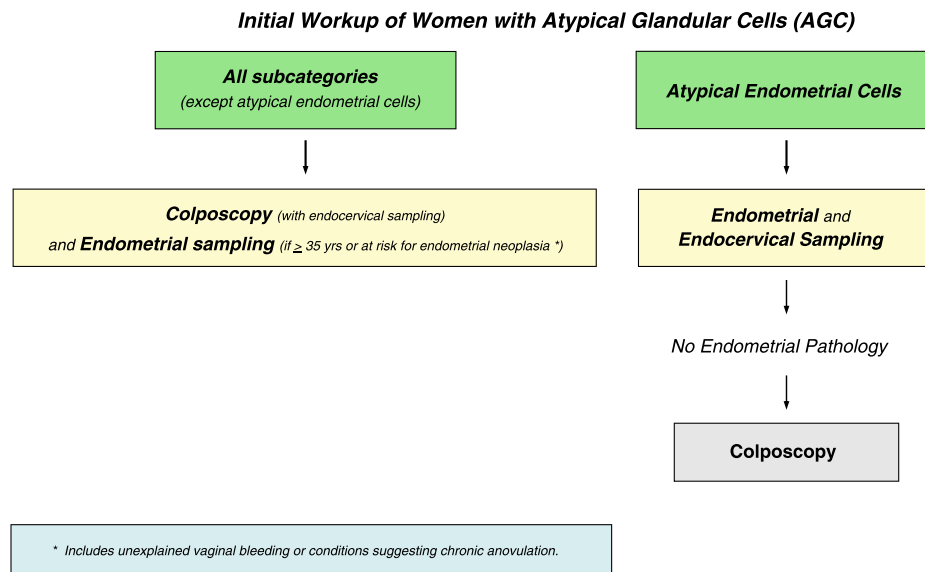
**HSIL in Special Populations**

**Women Aged 21–24 Years (Fig. 9).** For women aged 21–24 years with HSIL, colposcopy is recommended. Immediate treatment (ie, see-and-treat) is unacceptable. (AII) When CIN 2+ is not identified histologically, observation for up to 24 months using both colposcopy and cytology at 6-month intervals is recommended, provided the colposcopic examination is adequate and endocervical assessment is negative or CIN 1 (BIII). If CIN 2, CIN 3, or CIN 2,3 is identified histologically, management according to the 2012 consensus guideline for the management of young women with CIN 2, CIN 3, or CIN 2,3 is recommended (see “Management of Women With CIN

2, CIN 3, and CIN 2,3”). (BIII) If during follow-up a high-grade colposcopic lesion is identified or HSIL cytology persists for 1 year, biopsy is recommended. (BIII) If HSIL persists for 24 months without identification of CIN 2+, a diagnostic excisional procedure is recommended. (BIII) A diagnostic excisional procedure is recommended for women aged 21–24 years with HSIL when colposcopy is unsatisfactory or CIN 2, CIN 3, CIN 2,3, or ungraded CIN is identified on endocervical sampling. (BII) After two consecutive negative cytology results and no evidence of high-grade colposcopic abnormality, return to routine screening is recommended (BIII).

**Atypical Glandular Cells, Cytologic Adenocarcinoma In Situ, and Benign Glandular Changes**

An AGC interpretation is poorly reproducible (76) and uncommon (77). AGC has been associated with polyps and metaplasia but also with neoplasias, including adenocarcinomas of the endometrium, cervix, ovary, fallopian tube, and other sites (78). Neoplasia risk is higher when reported as AGC favor neoplasia or frank AIS. Although the cancer risk is lower in women younger than 35 years of age with AGC, the risk of CIN 2+ is higher, and intensive assessment is warranted at all ages (78). In the KPNC cohort, CIN 3+ was found in 9% of women aged 30 years and older with AGC cytology, with cancer in 3% (72, 77). Despite its



© Copyright , 2013, American Society for Colposcopy and Cervical Pathology. All rights reserved. 

**Figure 11.**

appellation, AGC cytology is most commonly associated with squamous lesions including CIN 1. However, glandular and squamous lesions often coexist, with CIN found in approximately half of women with AIS (79–81), so identification of CIN does not preclude AIS or adenocarcinoma. Although cervical adenocarcinoma is HPV associated and can be detected with HPV testing, endometrial cancer is not, so reflex HPV testing does not identify a subgroup of women who need less invasive assessment. A negative HPV test can be useful in identifying women at greater risk for endometrial rather than cervical disease (80). Endometrial cancer risk is low in young women without endometrial cancer risk factors but is substantially greater in older women and young women with risk factors.

Benign-appearing endometrial cells and stromal cells or histiocytes are rarely associated with premalignant lesions or cancer in young women. However, in postmenopausal women, these changes can be associated with an approximately 5% risk of clinically important pathology including endometrial adenocarcinoma (81).

### Management of Women With AGC or Cytologic AIS

#### Initial Workup (Fig. 11)

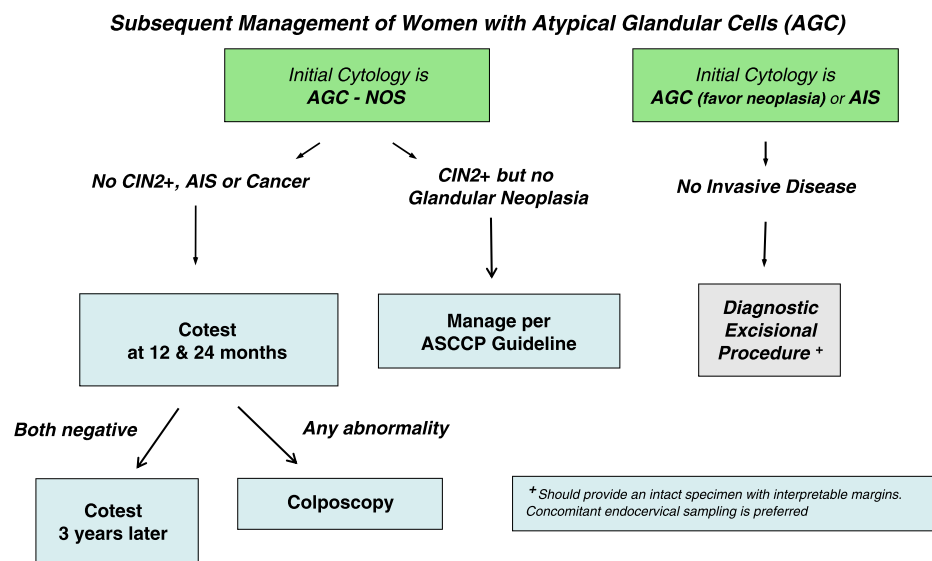
For women with all subcategories of AGC and AIS except atypical endometrial cells, colposcopy with endocervical sampling is recommended regardless of HPV result (AII). Accordingly, triage by reflex HPV testing

is not recommended, and triage using repeat cervical cytology is unacceptable (DII). Endometrial sampling is recommended in conjunction with colposcopy and endocervical sampling in women 35 years of age and older with all subcategories of AGC and AIS (BII). Endometrial sampling is also recommended for women younger than 35 years with clinical indications suggesting they may be at risk for endometrial neoplasia (BII). These include unexplained vaginal bleeding or conditions suggesting chronic anovulation. For women with atypical endometrial cells, initial evaluation limited to endometrial and endocervical sampling is preferred, with colposcopy acceptable either at the initial evaluation or deferred until the results of endometrial and endocervical sampling are known; if colposcopy is deferred and no endometrial pathology is identified, colposcopy is then recommended (AII).

#### Subsequent Management (Fig. 12)

For women with AGC not otherwise specified cytology in whom CIN 2+ is not identified, co-testing at 12 months and 24 months is recommended. If both co-tests are negative, return for repeat co-testing in 3 years is recommended. If any test is abnormal, colposcopy is recommended. (BII)

If CIN 2+ but no glandular neoplasia is identified histologically during the initial workup of a woman with atypical endocervical, endometrial, or glandular cells not



© Copyright, 2013, American Society for Colposcopy and Cervical Pathology. All rights reserved. ASCCP

**Figure 12.**

otherwise specified, management should be according to the 2012 consensus guidelines for the lesion found (CII).

For women with AGC “favor neoplasia” or endocervical AIS cytology, if invasive disease is not identified during the initial colposcopic workup, a diagnostic excisional procedure is recommended (AII).

It is recommended that the type of diagnostic excisional procedure used in this setting provide an intact specimen with interpretable margins (BII). Endocervical sampling after excision is preferred (BII).

### **AGC or Cytologic AIS in Special Populations**

#### **Pregnant Women**

The initial evaluation of AGC in pregnant women should be identical to that of nonpregnant women (BII), except that endocervical curettage and endometrial biopsy are unacceptable (EIII).

#### **Women Aged 21–24 Years**

It is recommended that ASCCP guidelines for management of AGC be followed for all women, including those aged 21–24 years (BII).

**Management of Benign Glandular Changes.** For asymptomatic premenopausal women with benign endometrial cells, endometrial stromal cells, or histiocytes, no further evaluation is recommended (BII). For postmenopausal women with benign endometrial cells, endometrial assessment is recommended (BII). For posthysterectomy pa-

tients with a cytologic report of benign glandular cells, no further evaluation is recommended (BII).

## **MANAGEMENT OF CIN AND HISTOLOGIC AIS**

### **CIN 1 and No CIN Found at Colposcopy After Abnormal Cytology**

CIN 1 is the histologic manifestation of HPV infection. Although most CIN 1 lesions are associated with oncogenic HPV, HPV-16 is less common in CIN 1 than in CIN 3, and nononcogenic HPV types are also commonly found in CIN 1 lesions (82, 83). The natural history of CIN 1 is similar to that of HPV-positive ASC-US and LSIL in the absence of CIN, suggesting similar management. Regression rates are high, especially in younger women (32, 64), and progression to CIN 2+ is uncommon (64, 84).

The risk of occult CIN 3+ among women with CIN 1 at colposcopic biopsy is linked to the risk conveyed by prior cytology. KPNC data showed similar, relatively low 5-year risk of CIN 3+ when CIN 1 or no lesion was diagnosed after ASC-US or LSIL, but a substantially higher risk after HSIL, ASC-H, and AGC. For example, women with CIN 1 after LSIL or HPV-positive ASC-US had a 5-year risk of CIN 3+ of 3.8%, while those with CIN 1 after HSIL had a 5-year risk of CIN 3+ of 15% (68).

Failure to detect CIN 2+ at colposcopy in women with HSIL does not mean that a CIN 2+ lesion has been excluded, although occult carcinoma is unlikely. As a result, women with HSIL who do not have immediate diagnostic excision require close follow-up. Few studies



of the natural history of HSIL managed without treatment have been reported, and follow-up in those is limited (68); management relies on expert opinion.

Women with minor cytologic abnormalities have similar risk for CIN 3+ whether colposcopy shows CIN 1 or no lesion (64, 68). Since CIN 3+ risk is elevated for women with either HPV-16 or HPV-18 or persistent oncogenic HPV infection of any type even when cytology is negative, guidelines must provide for follow-up for women with these “lesser abnormalities” even when no CIN is found. These “lesser abnormalities” include HPV-16 or HPV-18 positivity, persistent untyped oncogenic HPV, ASC-US, and LSIL.

The management of CIN 1 in endocervical samples merits special attention. Traditional management strategies prescribed excisional therapy for women with CIN on endocervical sampling. However, these strategies preceded full understanding of the high spontaneous regression rates of CIN 1. Endocervical samples are often contaminated by ectocervical lesions. Women with CIN 1 on endocervical sampling have a low risk for CIN 2+ (85, 86) (Fukuchi E, Fetterman B, Poitras N, Kinney W, Lorey T, Little RD. Risk of cervical precancer and cancer in women with cervical intraepithelial neoplasia grade 1 on endocervical curettage. *J Low Genit Tract Dis* [in press]). Current guidelines on management of CIN 1 on endocervical sampling do not apply when CIN 2, CIN 3, or CIN 2,3 is specified or when the

lesion seen cannot be graded, as an associated invasive cancer cannot be excluded without a diagnostic excision procedure.

**Management of Women With CIN 1 or No Lesion Preceded by “Lesser Abnormalities” (Fig. 13).** Co-testing at 1 year is recommended (BII). If both the HPV test and cytology are negative, then age-appropriate retesting 3 years later is recommended (cytology if age is younger than 30 years, co-testing if 30 years of age or older). If all tests are negative, then return to routine screening is recommended (BII). If any test is abnormal, then colposcopy is recommended (CIII).

If CIN 1 persists for at least 2 years, either continued follow-up or treatment is acceptable (CII). If treatment is selected and the colposcopic examination is adequate, either excision or ablation is acceptable (AI). A diagnostic excisional procedure is recommended if the colposcopic examination is inadequate; the endocervical sampling contains CIN 2, CIN 3, CIN 2,3 or ungraded CIN; or the patient has been previously treated (AIII). Treatment modality should be determined by the judgment of the clinician and should be guided by experience, resources, and clinical value for the specific patient (A1II). In patients with CIN 1 and an inadequate colposcopic examination, ablative procedures are unacceptable (EI). Podophyllin or podophyllin-related products are unacceptable for use in the vagina

**Management of Women with No Lesion or Biopsy-confirmed Cervical Intraepithelial Neoplasia - Grade 1 (CIN1) Preceded by “Lesser Abnormalities”<sup>∞\*</sup>**

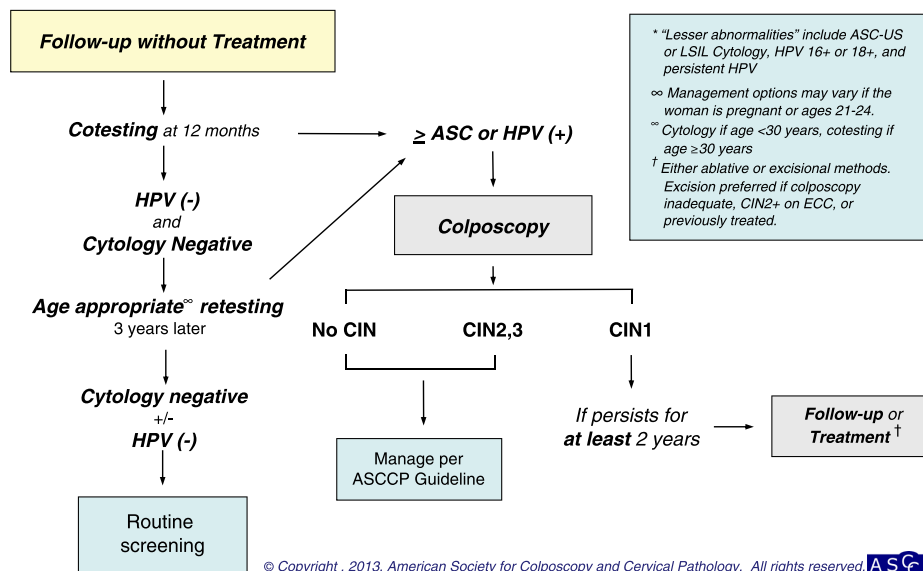
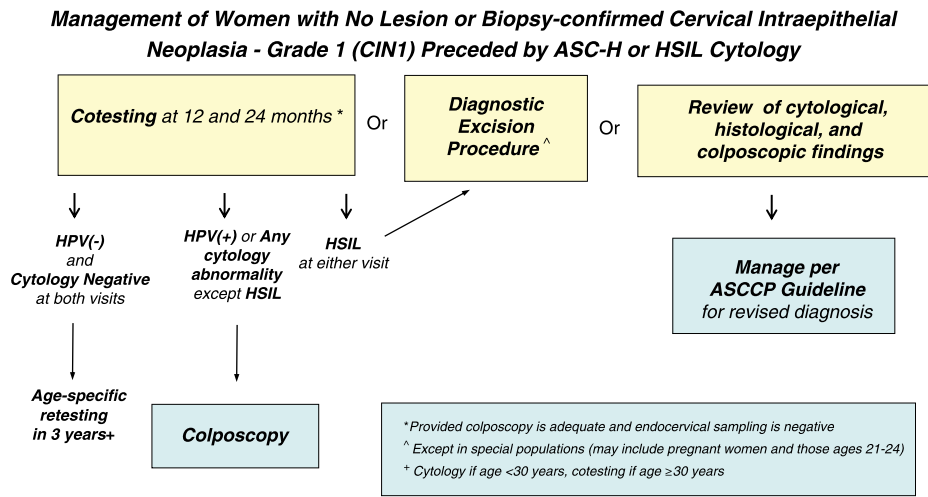


Figure 13.



© Copyright , 2013, American Society for Colposcopy and Cervical Pathology. All rights reserved. ASCCP

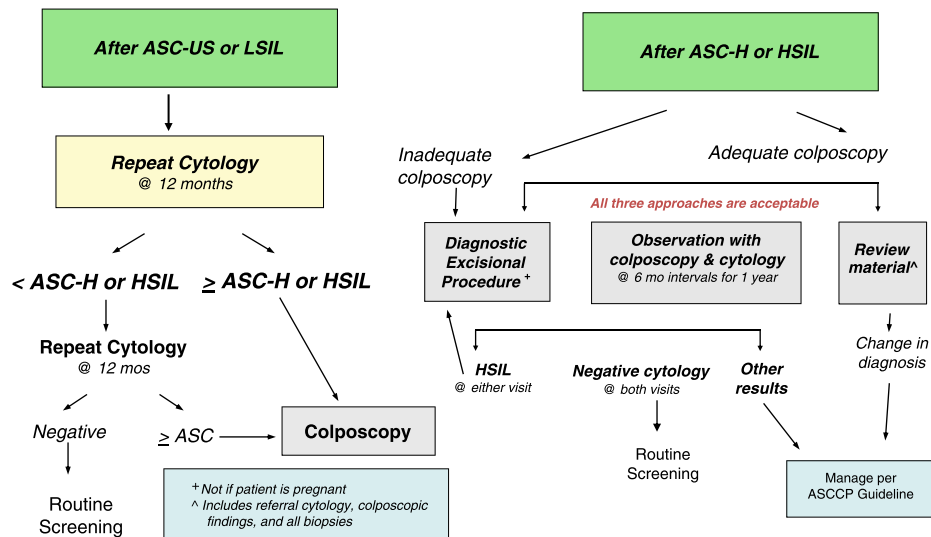
Figure 14.

or on the cervix (EII). Hysterectomy as the primary and principal treatment for histologically diagnosed CIN 1 is unacceptable (EII).

**Management of Women With CIN 1 or No Lesion Preceded by ASC-H or HSIL (Fig. 14).** When CIN 2+ is not identified histologically, either a diagnostic excisional procedure or observation with co-testing at 12 months and 24 months is recommended, provided in the latter case

that the colposcopic examination is adequate and the endocervical sampling is negative. (BIII). In this circumstance, it is acceptable to review the cytologic, histologic, and colposcopic findings; if the review yields a revised interpretation, management should follow guidelines for the revised interpretation (BII). If observation with co-testing is elected and both co-tests are negative, return for retesting in 3 years is recommended. If any test is abnormal, repeat colposcopy is recommended. A diagnostic

**Management of Women with No lesion or Biopsy-confirmed Cervical Intraepithelial Neoplasia - Grade 1 (CIN1) in Women Ages 21-24**



© Copyright, 2013, American Society for Colposcopy and Cervical Pathology. All rights reserved. ASCCP

Figure 15.

excisional procedure is recommended for women with repeat HSIL cytologic results at either the 1-year or 2-year visit (CIII).

**Management of Women With CIN 1 on Endocervical Sampling.** When CIN 1 is detected on endocervical sampling after lesser abnormalities but no CIN 2+ is detected in colposcopic biopsies, management should follow ASCCP management guidelines for CIN 1, with the addition of repeat endocervical sampling in 12 months (BII). For women with CIN 1 on endocervical sampling and cytology reported as ASC-H, HSIL, or AGC, or with a colposcopic biopsy reported as CIN 2+, management according to the ASCCP management guidelines for the specific abnormality is recommended (BII). For women not treated, repeat endocervical sampling at the time of evaluation for the other abnormality is recommended (BII).

### CIN 1 in Special Populations

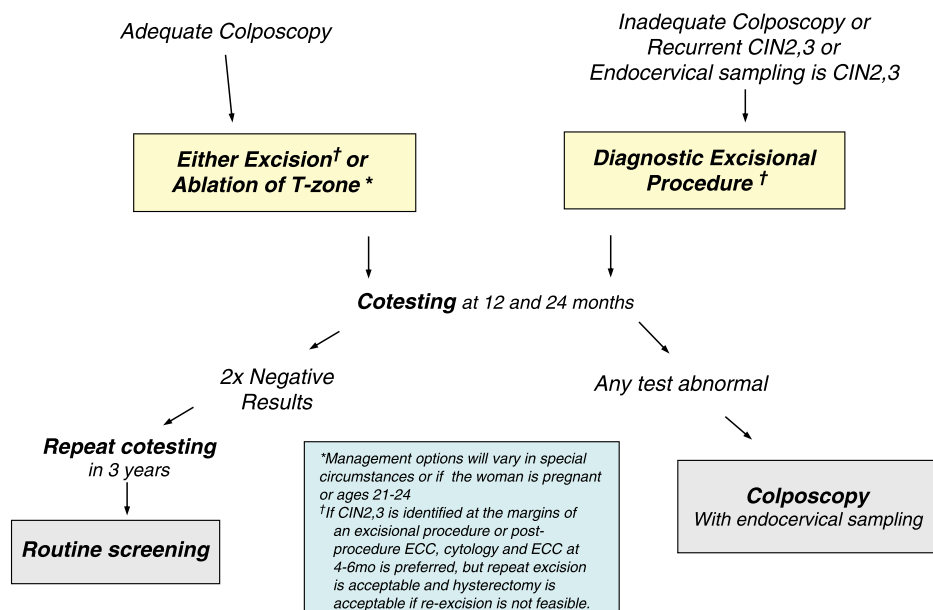
**Women Aged 21–24 Years (Fig. 15).** For women aged 21–24 years with CIN 1 after ASC-US or LSIL cytology, repeat cytology at 12-month intervals is recommended.

Follow-up with HPV testing is unacceptable (EII). For women with ASC-H or HSIL+ at the 12-month follow up, colposcopy is recommended. For women with ASC-US or worse at the 24 month follow up, colposcopy is recommended. After two consecutive negative tests, routine screening is recommended. (BII)

For women aged 21–24 years with CIN 1 after ASC-H or HSIL cytology, observation for up to 24 months using both colposcopy and cytology at 6-month intervals is recommended, provided the colposcopic examination is adequate and endocervical assessment is negative (BIII). If CIN 2, CIN 3, or CIN 2,3 is identified histologically, management should follow the guideline for the management of young women with CIN 2, CIN 3, or CIN 2,3 (BIII, see “Management of Women With CIN 2, CIN 3, and CIN 2,3”). If during follow-up a high-grade colposcopic lesion is identified or HSIL cytology persists for 1 year, biopsy is recommended (BIII). If HSIL persists for 24 months without identification of CIN 2+, a diagnostic excisional procedure is recommended (BIII). When colposcopy is inadequate or CIN 2, CIN 3, CIN 2,3 or ungraded CIN is identified on endocervical sampling, a diagnostic excision procedure is recommended (BII).

Regardless of antecedent cytology, treatment of CIN 1 in women aged 21–24 years is not recommended (BII).

### Management of Women with Biopsy-confirmed Cervical Intraepithelial Neoplasia - Grade 2 and 3 (CIN2,3) \*



© Copyright , 2013, American Society for Colposcopy and Cervical Pathology. All rights reserved. ASCCP

Figure 16.

**Pregnant Women.** For pregnant women with a histologic diagnosis of CIN 1, follow-up without treatment is recommended (BII). Treatment of pregnant women for CIN 1 is unacceptable.

### CIN 2, CIN 3, and CIN 2,3

While distinction between CIN 2 and CIN 3 is difficult in individual cases, regression rates are lower and progression to cancer more common for women with CIN 3 than for those with CIN 2 (87, 88). Cervical intraepithelial neoplasia 2 remains the consensus threshold for treatment in the United States, except in special circumstances. Women with unambiguous CIN 3 have the immediate precursor to invasive cancer and should not be observed, regardless of age or concern about future fertility.

After treatment for CIN 2+, recurrence risk remains well above that of women with negative co-test results throughout observation periods that have been reported to date (89). After two negative co-tests in the first 2 years after treatment, risk is similar to that of women with a negative Pap test, suggesting a 3-year interval between surveillance examinations (89). Whether routine screening may be appropriate after three or more negative co-tests is unclear.

The objective of screening during pregnancy is to identify cervical cancer. Cervical intraepithelial neoplasia 3

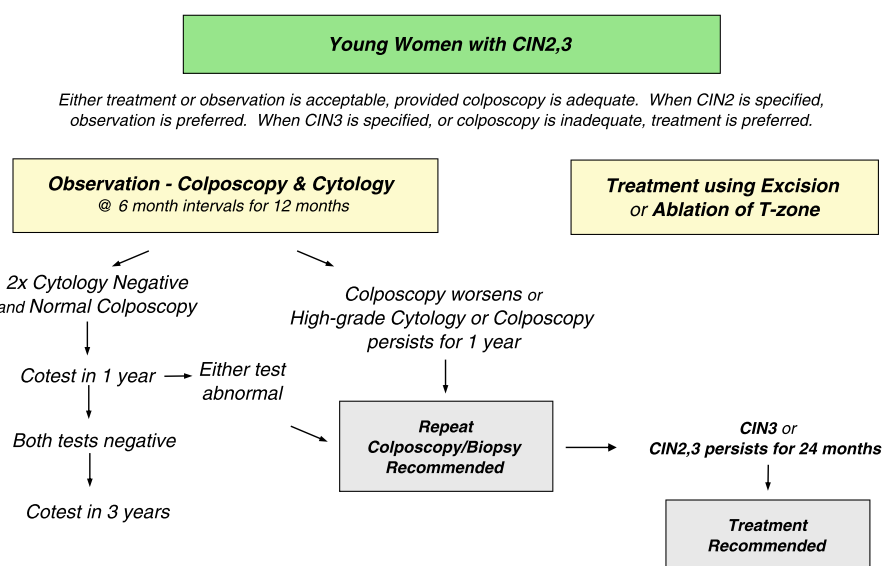
does not pose a risk to the pregnancy and poses no immediate risk to the mother. Treatment during pregnancy carries substantial risk for hemorrhage and pregnancy loss.

### Management of Women With CIN 2, CIN 3, and CIN 2,3 (Fig. 16)

**Initial Management.** For women with a histologic diagnosis of CIN 2, CIN 3, or CIN 2,3 and adequate colposcopy, both excision and ablation are acceptable treatment modalities, except in pregnant women and young women (AI). A diagnostic excisional procedure is recommended for women with recurrent CIN 2, CIN 3, or CIN 2,3 (AII). Ablation is unacceptable and a diagnostic excisional procedure is recommended for women with a histologic diagnosis of CIN 2, CIN 3, or CIN 2,3 and inadequate colposcopy or endocervical sampling showing CIN 2, CIN 3, CIN 2,3, or CIN not graded (AII). Observation of CIN 2, CIN 3, or CIN 2,3 with sequential cytology and colposcopy is unacceptable, except in pregnant women and young women (EII). Hysterectomy is unacceptable as primary therapy for CIN 2, CIN 3, or CIN 2,3 (EII).

**Follow-Up After Treatment.** For women treated for CIN 2, CIN 3, or CIN 2,3, co-testing at 12 months and 24 months is recommended (BII). If both co-tests are

### Management of Young Women with Biopsy-confirmed Cervical Intraepithelial Neoplasia - Grade 2,3 (CIN2,3) in Special Circumstances



© Copyright , 2013, American Society for Colposcopy and Cervical Pathology. All rights reserved. ASCCP

Figure 17.

negative, retesting in 3 years is recommended (BII). If any test is abnormal, colposcopy with endocervical sampling is recommended (BII). If all tests are negative, routine screening is recommended for at least 20 years, even if this extends screening beyond 65 years of age (CIII). Repeat treatment or hysterectomy based on a positive HPV test is unacceptable (EII).

If CIN 2, CIN 3, or CIN 2,3 is identified at the margins of a diagnostic excisional procedure or in an endocervical sample obtained immediately after the procedure, reassessment using cytology with endocervical sampling at 4–6 months after treatment is preferred (BII). Performing a repeat diagnostic excisional procedure is acceptable (CIII). Hysterectomy is acceptable if a repeat diagnostic procedure is not feasible (CIII).

A repeat diagnostic excisional procedure or hysterectomy is acceptable for women with a histologic diagnosis of recurrent or persistent CIN 2, CIN 3, or CIN 2,3 (BII).

#### CIN 2, CIN 3, or CIN 2,3 in Special Populations

**Young Women (Fig. 17).** For young women with a histologic diagnosis of CIN 2,3 not otherwise specified, either treatment or observation for up to 12 months using both colposcopy and cytology at 6-month intervals is acceptable, provided colposcopy is adequate. (BIII) When a histologic diagnosis of CIN 2 is specified for a young woman, observation is preferred but treatment is acceptable. If the colposcopic appearance of the lesion worsens or if HSIL cytology or a high-grade colposcopic lesion persists for 1 year, repeat biopsy is recommended (BIII).

After two consecutive negative cytology results, an additional co-test 1 year later is recommended (BIII). If the additional co-test is negative, then repeat co-testing in 3 years is recommended (BIII). Colposcopy is recommended if either the 2-year or 5-year co-test is abnormal (BIII).

Treatment is recommended if colposcopy is inadequate, if CIN 3 is specified, or if CIN 2 or CIN 2,3 persists for 24 months (BII). For women aged 21–24 years who are treated, follow-up according to ASCCP guidelines for treated CIN 2, CIN 3, or CIN 2,3 is recommended (BIII).

Treatment is recommended if CIN 3 is subsequently identified or if CIN 2, CIN 3, or CIN 2,3 persists for 24 months (BII).

**Pregnant Women.** In the absence of invasive disease or advanced pregnancy, additional colposcopic and cytologic examinations are acceptable in pregnant women

with a histologic diagnosis of CIN 2, CIN 3, or CIN 2,3 at intervals no more frequent than every 12 weeks (BII). Repeat biopsy is recommended only if the appearance of the lesion worsens or if cytology suggests invasive cancer (BII). Deferring reevaluation until at least 6 weeks postpartum is acceptable (BII). A diagnostic excisional procedure is recommended only if invasion is suspected (BII). Unless invasive cancer is identified, treatment is unacceptable (EII). Reevaluation with cytology and colposcopy is recommended no sooner than 6 weeks postpartum (CIII).

#### ADENOCARCINOMA IN SITU (AIS)

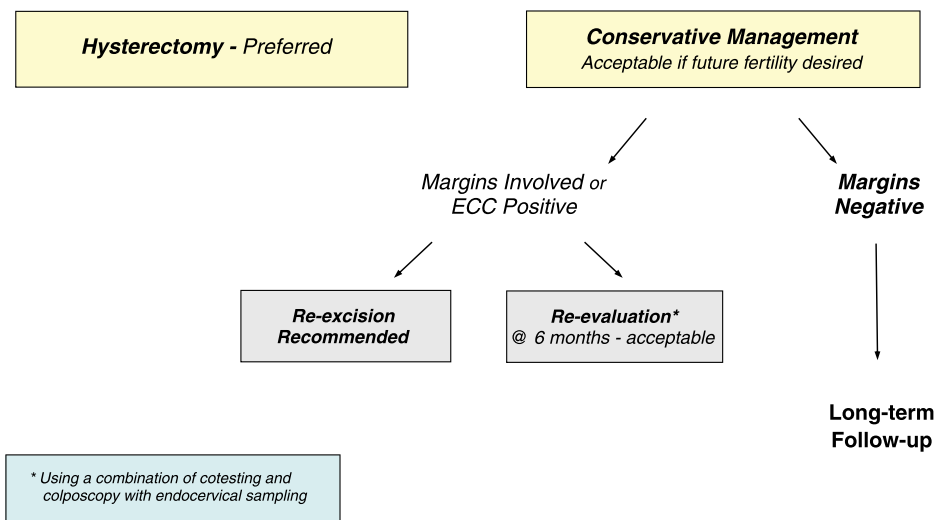
The incidence of AIS is low but rising (90). Management of AIS is controversial, as many assumptions used to justify conservative management for women with CIN 2 and CIN 3 do not apply. For example, colposcopic changes associated with AIS can be minimal, so determining the limits of a lesion can be difficult. AIS frequently extends into the endocervical canal, complicating determination of the desired depth of excision. AIS can be multifocal and discontinuous, so negative margins on an excision specimen do not provide assurance that the disease has been completely excised. Invasive cancer cannot be excluded without a diagnostic excisional procedure.

For these reasons, total hysterectomy remains the treatment of choice in women who have completed childbearing. For women who wish to maintain fertility, observation is an option, although it carries a less than 10% risk of persistent AIS and a small risk of cancer even when excision margins are negative (91–3). Like margin status, endocervical sampling at the time of an excisional procedure also predicts residual disease (94). Moreover, a negative HPV test after treatment identifies women at low risk for persistent or recurrent AIS (94). In 2001, knife conization was favored over loop excision because margin status and the interpretability of margins are critical to future treatment planning. In 2006, wording was changed to allow diagnostic excision using any modality, but care must be taken to keep the specimen intact and margins interpretable, avoiding fragmentation of the specimen, including “top-hat” serial endocervical excisions. This may require use of larger loops than those employed to excise visible squamous lesions.

#### Management of Women With AIS (Fig. 18)

Hysterectomy is preferred for women who have completed childbearing and have a histologic diagnosis of AIS on a specimen from a diagnostic excisional procedure

### Management of Women Diagnosed with Adenocarcinoma in-situ (AIS) during a Diagnostic Excisional Procedure



© Copyright , 2013, American Society for Colposcopy and Cervical Pathology. All rights reserved. ASCCP

Figure 18.

(BIII). Conservative management is acceptable if future fertility is desired (AII). If conservative management is planned and the margins of the specimen are involved or endocervical sampling obtained at the time of excision contains CIN or AIS, reexcision to increase the likelihood of complete excision is preferred. Reevaluation at 6 months using a combination of co-testing and colposcopy with endocervical sampling is acceptable in this circumstance. Long-term follow-up is recommended for women who do not undergo hysterectomy (CIII).

#### RECOMMENDATIONS FOR FUTURE RESEARCH

Literature review for the 2012 ASCCP Consensus Guidelines Conference identified several issues important to patient management that lack high-level evidence.

Follow-up is insufficient to determine posttreatment outcomes or optimal long-term follow-up intervals for women with treated CIN 2 and CIN 3 managed with serial co-testing. Evidence to guide management of women with negative colposcopy after abnormal cytology or with CIN 1 is also scanty. The path to routine screening for these women is based on consensus expert opinion and should be modified as evidence becomes available.

Follow-up studies of women managed using HPV genotyping, p16 and other immunostains, cytogenetics, and other markers are needed to guide their incorporation into management of cervical abnormalities.

The effect of HPV vaccination on large cohorts over long periods of follow-up remains to be studied, and whether prior HPV vaccination alters natural history or management of cytologic or histologic abnormalities remains unknown. Prospective study of the negative consequences of screening, diagnosis, and treatment are needed to allow balancing of risks and benefits.

Outcomes analyses using the LAST Project's two-tier squamous intraepithelial lesions (SIL) terminology are needed to direct how translation of three-tier CIN terminology to the two-tier terminology can be made and to define how specific management recommendations for histologic diagnoses in the two-tier system can be created (See Box 2). In particular, studies of the safety of observation for young women with histologic HSIL are needed, as reports to date have included diagnostic excision as a study endpoint. Estimates of regression and progression rates and the proportion of women who eventually require excision are needed. Long-term outcomes after apparent regression without treatment are unknown.

As the number and sophistication of tools applied to cervical cancer prevention continue to increase, the complexity of management promises to grow. Electronic medical records and bedside and pocket computers hold great promise for assisting clinicians and patients in negotiating this complexity. Development of risk scoring that incorporates past screening and treatment history into management decisions may help to balance risks and

benefits on a more individualized level than consensus guidelines. Future consensus conferences will be needed to integrate new approaches.

## REFERENCES

- Solomon D, Davey D, Kurman R, Moriarty A, O'Connor D, Prey M, et al. The 2001 Bethesda System: terminology for reporting results of cervical cytology. *JAMA* 2002; 287:2114–9.
- ASC-US-LSIL Triage Study (ALTS) Group. Results of a randomized trial on the management of cytology interpretations of atypical squamous cells of undetermined significance. *Am J Obstet Gynecol* 2003;188:1383–92.
- ASC-US-LSIL Triage Study (ALTS) Group. A randomized trial on the management of low-grade squamous intraepithelial lesion cytology interpretations. *Am J Obstet Gynecol* 2003;188:1393–400.
- Wright TC, Cox JT, Massad LS, Twigg LB, Wilkinson EJ. 2001 Consensus guidelines for the management of women with cervical cytological abnormalities and cervical cancer precursors: Part 1: Cytological abnormalities. *JAMA* 2002; 287: 2120–9.
- Wright TC Jr, Cox JT, Massad LS, Carlson J, Twigg LB, Wilkinson EJ; 2001 ASCCP-sponsored Consensus Workshop. 2001 consensus guidelines for the management of women with cervical intraepithelial neoplasia. *J Low Genit Tract Dis*. 2003 Jul;7(3):154–67.
- Wright TC Jr, Massad LS, Dunton CJ, Spitzer M, Wilkinson EJ, Solomon D; 2006 ASCCP-Sponsored Consensus Conference. 2006 consensus guidelines for the management of women with abnormal cervical screening tests. *J Low Genit Tract Dis* 2007;11:201–22.
- Wright TC, Massad LS, Dunton CJ, Spitzer M, Wilkinson EJ, Solomon D for the 2006 ASCCP-sponsored consensus conference. 2006 consensus guidelines for the management of women with cervical intraepithelial neoplasia or adenocarcinoma in-situ. *Am J Obstet Gynecol*. 2007;197:340–5.
- Davey DD, Austin RM, Birdsong G, Buck HW, Cox JT, Darragh TM, et al. ASCCP patient management guidelines: Pap test specimen adequacy and quality indicators. *J Low Genit Tract Dis* 2002;6:195–9.
- Davey DD, Cox JT, Austin RM, Birdsong G, Colgan TJ, Howell LP, et al. Cervical cytology specimen adequacy: Updated patient management guidelines. *J Low Genit Tract Dis* 2008;12:71–81.
- Saslow D, Solomon D, Lawson HW, Killackey M, Kulasingam SL, Cain J et al. American Cancer Society, American Society for Colposcopy and Cervical Pathology, and American Society for Clinical Pathology screening guidelines for the prevention and early detection of cervical cancer. *CA Cancer J Clin* 2012;62:147–72.
- Moyer VA, LeFevre ML, Siu AL, Bibbins-Domingo K, Curry SJ, Flores G, et al for the U.S. Preventive Services Task Force. Screening for cervical cancer: U.S. Preventive Services Task Force recommendation statement. *Ann Intern Med*. 2012;156:880–91.
- Katki HA, Schiffman M, Castle PE, Fetterman B, Poitras NE, Thomas Lorey T, et al. Benchmarking CIN3+ risk as the basis for incorporating HPV and Pap cotesting into cervical screening and management guidelines. *J Lower Genit Tract Dis* 2013;17:S28–S35.
- Castle PE, Sideri M, Jeronimo J, Solomon D, Schiffman M. Risk assessment to guide the prevention of cervical cancer. *J Low Genit Tract Dis* 2008;12:1–7
- Darragh TM, Colgan TJ, Cox JT, Heller DS, Henry MR, Luff RD, et al; Members of LAST Project Work Groups. The Lower Anogenital Squamous Terminology Standardization Project for HPV-associated lesions: background and consensus recommendations from the College of American Pathologists and the American Society for Colposcopy and Cervical Pathology. *J Low Genit Tract Dis* 2012;16:205–42.
- Mogensen ST, Bak M, Dueholm M, Frost L, Knolblaugh NO, Praest J, et al. Cytobrush and endocervical curettage in the diagnosis of dysplasia and malignancy of the uterine cervix. *Acta Obstet Gynecol Scand* 1997;76:69–73.
- Goksedef BP, Api M, Kaya O, Gorgen H, Tarlaci A, Cetin A. Diagnostic accuracy of two endocervical sampling method: randomized controlled trial. *Arch Gynecol Obstet* 2013;287:117–22.
- Martin-Hirsch PPL, Paraskevaidis E, Bryant A, Dickinson HO, Keep SL. Surgery for cervical intraepithelial neoplasia. *Cochrane Database of Systematic Reviews* 2010, Issue 6. Art. No.: CD001318. DOI: 10.1002/14651858.CD001318.pub2.
- Kyrgiou M, Tsoumpou I, Vrekoussis T, Martin-Hirsch P, Arbyn M, Prendiville W, et al. The up-to-date evidence on colposcopy practice and treatment of cervical intraepithelial neoplasia: the Cochrane colposcopy and cervical cytology collaborative group (C5 group) approach. *Cancer Treat Rev* 2006;32:516–23.
- Nuovo J, Melnikow J, Willan AR, Chan BK. Treatment outcomes for squamous intraepithelial lesions. *Int J Gynaecol Obstet* 2000;68:25–33.
- Kalliala I, Nieminen P, Dyba T, Pukkala E, Anttila A. Cancer free survival after CIN treatment: comparisons of treatment methods and histology. *Gynecol Oncol* 2007;105: 228–33.
- Paraskevaidis E, Arbyn M, Sotiriadis A, Diakomanolis E, Martin-Hirsch P, Koliopoulos G, et al. The role of HPV DNA testing in the follow-up period after treatment for CIN: a systematic review of the literature. *Cancer Treat Rev* 2004; 30:205–11.
- Jakobsson M, Gissler M, Paavonen J, Tapper AM. Long-term mortality in women treated for cervical intraepithelial neoplasia. *BJOG* 2009;116:838–44.
- Kalogirou D, Antoniou G, Karakitsos P, Potsis D, Kalogirou O, Giannikos L. Predictive factors used to justify

hysterectomy after loop conization: increasing age and severity of disease. *Eur J Gynaecol Oncol* 1997;18:113–6.

24. Ghaem-Maghami S, Sagi S, Majeed G, Soutter WP. Incomplete excision of cervical intraepithelial neoplasia and risk of treatment failure: a meta-analysis. *Lancet Oncol* 2007; 8:985–93.

25. Kocken M, Uijterwaal MH, de Vries AL, Berkhof J, Ket JC, Helmerhorst TJ, et al. High-risk human papillomavirus testing versus cytology in predicting post-treatment disease in women treated for high-grade cervical disease: a systematic review and meta-analysis. *Gynecol Oncol* 2012;125:500–7.

26. Katki HA, Schiffman M, Castle PE, Fetterman B, Poitras NE, Lorey T, et al. Five-Year Risk of CIN 3+ and Cervical Cancer Among Women With HPV Testing of ASC-US Pap Results. *J Low Genit Tract Dis* 2013;17:S36–S42.

27. Jakobsson M, Gissler M, Paavonen J, Tapper AM. Loop electrosurgical excision procedure and the risk for preterm birth. *Obstet Gynecol* 2009;114:504–10.

28. Sadler L, Saftlas A, Wang W, Exeter M, Whittaker J, McCowan L. Treatment for cervical intraepithelial neoplasia and risk of preterm delivery. *JAMA* 2004;29:2100–6.

29. Bruinsma FJ, Quinn MA. The risk of preterm birth following treatment for precancerous changes in the cervix: a systematic review and meta-analysis. *BJOG* 2011;118:1031–41.

30. Khalid S, Dimitriou E, Conroy R, Paraskevaides E, Kyrgiou M, Harrity C, et al. The thickness and volume of LLETZ specimens can predict the relative risk of pregnancy-related morbidity. *BJOG* 2012;119:685–91.

31. Moscicki AB, Ma Y, Wibblesman C, Darragh TM, Powers A, Farhat S, et al. Rate of and risks for regression of cervical intraepithelial neoplasia 2 in adolescents and young women. *Obstet Gynecol* 2010;116:1373–80.

32. Moscicki AB, Shiboski S, Hills NK, Powell KJ, Jay N, Hanson EN, et al. Regression of low-grade squamous intraepithelial lesions in young women. *Lancet*. 2004;364:1678–83.

33. Katki HA, Schiffman M, Castle PE, Fetterman B, Poitras NE, Lorey T, et al. Five-Year Risk of CIN 3+ to Guide the Management of Women Aged 21 to 24 Years. *J Low Genit Tract Dis* 2013;17:S64–S68.

34. Moscicki AB, Cox JT. Practice improvement in cervical screening and management (PICSM): symposium on management of cervical abnormalities in adolescents and young women. *J Low Genit Tract Dis*. 2010 Jan;14:73–80.

35. Benard VB, Watson M, Castle PE, Saraiya M. Cervical Cancer Rates Among Young Females in the United States. *Obstet Gynecol* 2012;120:1117–23.

36. Winer RL, Lee SK, Hughes JP, Adam DE, Kiviat NB, Koutsky LA. Genital human papillomavirus infection: incidence and risk factors in a cohort of female university students. *Am J Epidemiol*. 2003;157:218–26.

37. Moscicki AB, Hills N, Shiboski S, Powell K, Jay N, Hanson E, et al. Risks for incident human papillomavirus infection and low-grade squamous intraepithelial lesion development in young females. *JAMA*. 2001;285:2995–3002.

38. Sharp L, Cotton S, Carsin AE, Gray N, Thornton A, Cruickshank M, et al on behalf of the TOMBOLA Group. Factors associated with psychological distress following colposcopy among women with low-grade abnormal cervical cytology: a prospective study within the Trial Of Management of Borderline and Other Low-grade Abnormal smears (TOMBOLA). *Psychooncology*. 2011 Dec 12. doi: 10.1002/pon.2097. [Epub ahead of print]

39. Kahn J, Slap G, Bernstein D, Kollar L, Tissot A, Hillard P, et al. Psychological, behavioral, and interpersonal impact of human papillomavirus and Pap test results. *J Womens Health* 2005;14:650–9.

40. Kahn J, Slap G, Bernstein D, Tissot A, Kollar L, Hillard P, et al. Personal Meaning of Human Papillomavirus and Pap Test Results in Adolescent and Young Adult Women. *Health Psychol* 2007;26:192–200.

41. Lerner D, Parsons SK, Justicia-Linde F, Chelmos D, Chang H, Rogers WH, et al. The impact of pre-cancerous cervical lesions on functioning at work and work productivity. *J Occup Environ Med*. 2010;52:926–33.

42. Moriarty AT, Clayton AC, Zaleski S, Henry MR, Schwartz MR, Eversole GM, et al. Unsatisfactory reporting rates: 2006 practices of participants in the College of American Pathologists interlaboratory comparison program in gynecologic cytology. *Arch Pathol Lab Med*. 2009;133:1912–6.

43. Hoda RS, Loukeris K, Abdul-Karim FW. Gynecologic cytology on conventional and liquid-based preparations: A comprehensive review of similarities and differences. *Diagn Cytopathol*. 2012 Apr 17. doi: 10.1002/dc.22842. [Epub ahead of print].

44. Hock YL, Ramaiah S, Wall ES, Harris AM, Marston L, Marshall J, et al. Outcome of women with inadequate cervical smears followed up for five years. *J Clin Pathol* 2003; 56:592–5

45. Ransdell JS, Davey DD, Zaleski S. Clinicopathologic correlation of the unsatisfactory Papanicolaou smear. *Cancer (Cancer Cytopathol)* 1997;81:139–43.

46. Siebers AG, Klinkhamer PJJM, Vedder JEM, Arbyn M, Bulten J. Causes and relevance of unsatisfactory and satisfactory but limited smears of liquid-based compared with conventional cervical cytology. *Arch Pathol Lab Med* 2012;136:76–83

47. Zhao C, Austin RM. High-risk human papillomavirus DNA test results are useful for disease risk stratification in women with unsatisfactory liquid-based cytology Pap test results. *J Lower Genit Tract Dis* 2009;13:79–84.

48. Holton T, Smith D, Terry M, Madgwick A, Levine T. The effect of lubricant contamination on ThinPrep liquid-based preparations. *Cytopathology* 2008;19:236–43.

49. Buntinx F, Brouwers M. Relation between sampling device and detection of abnormality in cervical smears: a meta-analysis of randomized and quasi-randomised studies. *BMJ* 1996;313:1285–90.

50. Martin-Hirsch P, Jarvis G, Kitchener H, Lilford R. Collection devices for obtaining cervical cytology samples. *Cochrane Database Syst Rev* 2000;CD001036.



51. Huang A, Quinn M, Tan J. Outcome in women with no endocervical component on cervical cytology after treatment for high-grade cervical dysplasia. *Aust N Z J Obstet Gynaecol* 2009;49:426–8.
52. Mitchell H, Hocking J, Saville M. Cervical cytology screening history of women diagnosed with adenocarcinoma in situ of the cervix. A case-control study. *Acta Cytol* 2004;48:595–600.
53. Mitchell HS. Longitudinal analysis of histologic high-grade disease after negative cervical cytology according to endocervical status. *Cancer* 2001;93:237–40.
54. Elumir-Tanner L, Doraty M. Management of Papanicolaou test results that lack endocervical cells. *CMAJ* 2011;183:563–8.
55. Zhao C, Austin RM. Human papillomavirus DNA detection in ThinPrep Pap test vials is independent of cytologic sampling of the transformation zone. *Gynecol Oncol* 2007;107:231–5.
56. Huang A, Quinn M, Tan J. Outcome in women with no endocervical component on cervical cytology after treatment for high-grade cervical dysplasia. *Aust NZ J Obstet Gynaecol* 2009;49:426–8.
57. Katki HA, Kinney WK, Fetterman B, Lorey T, Poitras NE, Cheung L, et al. Cervical cancer risk for women undergoing concurrent testing for human papillomavirus and cervical cytology: a population-based study in routine clinical practice. *Lancet Oncol*. 2011;12:663–72.
58. Katki HA, Schiffman M, Castle PE, Fetterman B, Poitras NE, Lorey T, et al. Five-Year Risks of CIN 3+ and Cervical Cancer Among Women Who Test Pap-Negative But Are HPV-Positive. *J Low Genit Tract Dis* 2013;17:S56–S63.
59. Castle PE, Rodríguez AC, Burk RD, Herrero R, Wacholder S, Alfaro M, et al for the Proyecto Epidemiológico Guanacaste (PEG) Group. Short term persistence of human papillomavirus and risk of cervical precancer and cancer: population based cohort study. *BMJ*. 2009;339:b2569. doi: 10.1136/bmj.b2569.
60. Rodríguez AC, Schiffman M, Herrero R, Wacholder S, Hildesheim A, Castle PE, et al for the Proyecto Epidemiológico Guanacaste Group. Rapid clearance of human papillomavirus and implications for clinical focus on persistent infections. *J Natl Cancer Inst* 2008;100:513–7.
61. Stoler MH, Wright TC, Sharma A, Apple R, Gutekunst K, Wright TL. High-risk human papillomavirus testing in women with ASC-US cytology: results from the ATHENA HPV study. *Am J Clin Pathol* 2011;135:466–75.
62. Einstein MH, Martens MG, Garcia FA, Ferris DG, Mitchell AL, Day SP, et al. Clinical validation of the Cervista HPV HR and 16/18 genotyping tests for use in women with ASC-US cytology. *Gynecol Oncol* 2010;118:116–22.
63. Gage JC, Schiffman M, Solomon D, Wheeler CM, Castle PE. Comparison of measurements of human papillomavirus persistence for postcolposcopic surveillance for cervical precancerous lesions. *Cancer Epidemiol Biomarkers Prev*. 2010;19:1668–74.
64. Cox JT, Schiffman M, Solomon D. Prospective follow-up suggests similar risk of subsequent cervical intraepithelial neoplasia grade 2 or 3 among women with cervical intraepithelial neoplasia grade 1 or negative colposcopy and directed biopsy. *Am J Obstet Gynecol* 2003;188:1406–12.
65. Moore G, Fetterman B, Cox JT, Poitras N, Lorey T, Kinney W, et al. Lessons from practice: risk of CIN3 or cancer associated with an LSIL or HPV-positive ASC-US screening result in women aged 21–24. *J Lower Genit Tract Dis* 2010;14:97–102.
66. Arbyn M, Sasieni P, Meijer CJ, Clavel C, Koliopoulos G, Dillner J. Chapter 9: clinical applications of HPV testing : a summary of meta-analyses. *Vaccine* 2006;24 (suppl 3):S78–S89.
67. Katki HA, Schiffman M, Castle PE, Fetterman B, Poitras NE, Lorey T, et al. Five-Year Risks of CIN 2+ and CIN 3+ Among Women With HPV-Positive and HPV-Negative LSIL Pap Results. *J Low Genit Tract Dis* 2013;17:S43–S49.
68. Katki HA, Gage JC, Schiffman M, Castle PE, Fetterman B, Poitras NE, et al. Follow-up Testing After Colposcopy: Five-Year Risk of CIN 2+ After a Colposcopic Diagnosis of CIN 1 or Less. *J Low Genit Tract Dis* 2013;5:S69–S77.
69. Massad LS, Collins YC, Meyer PM. Biopsy correlates of abnormal cervical cytology classified using the Bethesda system. *Gynecol Oncol* 2001;82:516–22.
70. Alvarez RD, Wright TC. Effective cervical neoplasia detection with a novel optical detection system: a randomized trial. *Gynecol Oncol* 2007;104:281–9.
71. Dunn TS, Burke M, Shwayder J. A “see and treat” management for high grade squamous intraepithelial lesion Pap smears. *J Lower Gen Tract Dis* 2003;7:104–6.
72. Katki HA, Schiffman M, Castle PE, Fetterman B, Poitras NE, Lorey T, et al. Five-year risk of cervical cancer and CIN3 for HPV-positive and HPV-negative high-grade Pap results. *J Low Genit Tract Dis* 2013;17:S50–S55.
73. Pretorius RG, Zhange WH, Belinson JL, Huang MN, Wu LY, Zhange X, et al. Colposcopically directed biopsy, random cervical biopsy, and endocervical curettage in the diagnosis of Cervical intraepithelial neoplasia II or worse. *Am J Obstet Gynecol* 2004;191:430–4.
74. Gage JC, Hanson VW, Abbey K, Dipery S, Gardner S, Kubota J, et al. Number of cervical biopsies and sensitivity of colposcopy. *Obstet Gynecol* 2006;108:264–72.
75. Guido R, Schiffman M, Solomon D, Burke L for the ASCUS/LSIL Triage Study (ALTS) Group. Post-colposcopy management strategies for women referred with low-grade squamous intraepithelial lesions of human papillomavirus DNA-positive atypical squamous cells of undetermined significance: a two-year prospective trial. *Am J Obstet Gynecol* 2003;188:1401–5.
76. Lee KR, Darragh TM, Joste NE, Krane JF, Sherman ME, Hurlley LB, et al. Atypical glandular cells of undetermined significance (AGUS): interobserver reproducibility in cervical smears and corresponding thin-layer preparations. *Am J Clin Pathol* 2002;117:96–102.

77. Davey DD, Neal MH, Wilbur DC, Colgan TJ, Styer PE, Mody DR. Bethesda 2001 implementation and reporting rates: 2003 practices of participants in the College of American Pathologists Interlaboratory Comparison Program in Cervicovaginal Cytology. *Arch Pathol Lab Med* 2004;128:1224–9.
78. Zhao C, Florea A, Onisko A, Austin RM. Histologic follow-up results in 662 patients with Pap test findings of atypical glandular cells: results from a large academic womens hospital laboratory employing sensitive screening methods. *Gynecol Oncol* 2009;114:383–9.
79. Sharpless KE, Schnatz PF, Mandavilli S, Greene JF, Sorosky JL. Dysplasia associated with atypical glandular cells on cervical cytology. *Obstet Gynecol* 2005;105:494–500.
80. Castle PE, Fetterman M, Poitras N, Lorey T, Shaber R, Kinney W. Relationship of atypical glandular cell cytology, age and human papillomavirus detection to cervical and endometrial cancer risks. *Obstet Gynecol* 2010;115:243–8.
81. Simsir A, Carter W, Elgert P, Cangiarella J. Reporting endometrial cells in women 70 years and older: assessing the clinical usefulness of Bethesda 2001. *Am J Clin Pathol* 2005;123:571–5.
82. Schlecht NF, Platt RW, Duarte-Franco E, Costa MC, Sobrinho JP, Prado JC, et al. Human papillomavirus infection and time to progression and regression of cervical intraepithelial neoplasia. *J Natl Cancer Inst* 2003;95:1336–43.
83. Sideri M, Iqidbashian S, Boveri S, Radice D, Casadio C, Spolti N, et al. Age distribution of HPV genotypes in cervical intraepithelial neoplasia. *Gynecol Oncol* 2011;212:510–3.
84. Trimble CL, Piantadosi S, Gravitt P, Ronnett B, Pizer E, Elko A, et al. Spontaneous regression of high-grade cervical dysplasia: effects of human papillomavirus type and HLA phenotype. *Clin Cancer Res*. 2005;11:4717–23.
85. Petersen S, Belnap C, Larsen WI, Farley J. Grading of squamous dysplasia in endocervical curettage specimens: The case for conservative management of mild endocervical dysplasia. *J Reprod Med*. 2007;52:917–21.
86. Gage JC, Duggan MA, Nation JG, Gao S, Castle PE. Comparative risk of high-grade histopathology diagnosis following a CIN1 finding in endocervical curettage vs. cervical biopsy. *J Lower Genit Tract Dis* 2012;17:137–41.
87. Ostor AG. Natural history of cervical intraepithelial neoplasia: A critical review. *Intern J Gynecol Pathol* 1993;12:186–92.
88. Holowaty P, Miller AB, Rohan T, To T. Natural history of dysplasia of the uterine cervix. *J Natl Cancer Inst* 1999;91:252–8.
89. Katki HA, Schiffman M, Castle PE, Fetterman B, Poitras NE, Lorey T, et al. Five-Year Risk of Recurrence After Treatment of CIN 2, CIN 3, or AIS: Performance of HPV and Pap Cotesting in Posttreatment Management. *J Low Genit Tract Dis* 2013;17:S78–S84.
90. Sherman ME, Wang SS, Carreon J, Devesa SS. Mortality trends for cervical squamous and adenocarcinoma in the United States. Relation to incidence and survival. *Cancer*. 2005;103:1258–64.
91. Bull-Phelps SL, Garner EI, Walsh CS, Gehrig PA, Miller DS, Schorge JO. Fertility-sparing surgery in 101 women with adenocarcinoma in situ of the cervix. *Gynecol Oncol* 2007;107:316–9.
92. Costa S, Venturoli S, Negri G, Sideri M, Preti M, Pesaresi M, et al. Factors predicting the outcome of conservatively treated adenocarcinoma in situ of the uterine cervix: an analysis of 166 cases. *Gynecol Oncol* 2012;124:490–5.
93. van Hanegem N, Barroilhet LM, Nucci MR, Bernstein M, Feldman S. Fertility-sparing treatment in younger women with adenocarcinoma in situ of the cervix. *Gynecol Oncol* 2012;124:72–7.
94. Lea JS, Shin CH, Sheets EE, Coleman RL, Gehrig PA, Duska LR, et al. Endocervical curettage at conization to predict residual cervical adenocarcinoma in situ. *Gynecol Oncol* 2002;87:129–32.

#### APPENDIX A: ADDITIONAL COAUTHOR PARTICIPANTS, ACKNOWLEDGED NONAUTHOR DELEGATES, AND PARTICIPATING ORGANIZATIONS

See Appendix 2, available online at <http://links.lww.com/LGT/A10>, for financial disclosure information from the coauthor delegates.

**Coauthor Delegates:** Deborah Arrindell; James R. Bentley, MD; Monique A. Bertrand, MD; Lori A. Boardman, MD; Philip E. Castle, PhD, MPH; David Chelmow, MD; Janie Daddario, MSN, WHNP-BC; Diane D. Davey, MD; Linda Dominguez, CNP, RN; Levi S. Downs, Jr., MD; Patricia Fontaine, MD, MS; Julia C. Gage, PhD, MPH; Francisco A.R. Garcia, MD, MPH; Mohiedean Ghofrani, MD, MBA; Richard S. Guido, MD; Eric C. Huang, MD, PhD; Versie Johnson-Mallard, PhD, ARNP; Elizabeth A. Kostas-Polston, PhD, APRN, WHNP-BC; Robert Kurman, MD; Susan M. McFaul, MD; Deborah L. Nucatola, MD; R. Patricia P. Power, MD; Walter Prendiville, MD; Debbie Saslow, PhD; Karen Shea, MSN, WHNP-BC; Mary K. Sidawy, MD; Mario Sideri, MD; Kate Simon, PhD; Silvio Tatti, MD; Jeffrey Waldman, MD; Jason D. Wright, MD; Fred Wyand; and Laurie C. Zephyrin, MD, MPH, MBA

**Nonauthor Delegates Whose Contribution is Acknowledged:** Vicki B. Benard, PhD; Natalia Comella, PhD; MariBeth Gagnon, MS CT(ASCP) HTL; Ann Laros, MD; Mona Saraiya, MD, MPH; Elizabeth R. Unger, PhD, MD; and Rose H. Xu, PharmD, MSc.

**Participating Organizations:** American Academy of Family Physicians; American Board of Pathology; American Cancer Society; American College Health

Association; American College of Obstetricians and Gynecologists; American Social Health Association; American Society for Colposcopy and Cervical Pathology; American Society for Cytopathology; Association of Reproductive Health Professionals; CDC - Division of Cancer Prevention and Control; CDC - Division of High-Consequence Pathogens and Pathology; CDC - Division of Laboratory Science & Standards; College of American Pathologists; Food & Drug Administration; International Federation for Cervical Pathology and Colposcopy; International Gynecologic Cancer Society; National Cancer Institute; Nurse Practitioners in Women's Health; Planned Parenthood Federation of America; Society of Canadian Colposcopists; Society of Gynecologic Oncologists; Society of Obstetricians and Gynaecologists of Canada; and Women Veterans Health Strategic Healthcare Group.

#### APPENDIX B: DEFINITION OF TERMS

*Colposcopy* is the examination of the cervix, vagina, and, in some instances the vulva, with a colposcope after the application of a 3% to 5% acetic acid solution coupled with obtaining colposcopically directed biopsies of all lesions suspected of representing neoplasia.

*Adequate colposcopy* indicates that the entire squamocolumnar junction and the margins of any visible lesion can be visualized with the colposcope.

*Co-testing* is assessment for cervical disease using a combination of cytology and HPV testing at the same time, regardless of the cytology result.

*Reflex HPV testing* is the performance of HPV testing only in response to an abnormality to stratify risk and guide further management.

*Endometrial sampling* includes obtaining a specimen for histologic evaluation using an endometrial biopsy, dilation and curettage, or hysteroscopy.

*Endocervical sampling* includes obtaining a specimen for either histologic evaluation using an endocervical curette or a cytobrush or for cytologic evaluation using a cytobrush.

*Endocervical assessment* is the process of evaluating the endocervical canal for the presence of neoplasia using either a colposcope or endocervical sampling.

*Diagnostic excisional procedure* is the process of obtaining a specimen from the transformation zone and endocervical canal for histologic evaluation and includes laser conization, cold-knife conization, loop or needle electro-surgical excision, and loop electro-surgical conization.

*Lesser abnormalities* are those that carry lower risk of CIN 3+ than other results. These include negative cytology with either HPV-16 or HPV-18 or persistent untyped oncogenic HPV, ASC-US, and LSIL.

*HPV, human papillomavirus; CIN, cervical intraepithelial neoplasia; ASC-US, atypical squamous cells of undetermined significance; LSIL, low-grade squamous intraepithelial lesions.*